CASE REPORT

Lung Adenocarcinoma Developing Pleomorphic Carcinoma With *ERBB3* Amplification After Acquired Resistance to Sotorasib: A Case Report

Satoru Senoo, MD, PhD,[a,*] Kohei Takata, MD,[a] Shunsuke Matsumori, MD,[a] Takahiro Baba, MD,[a] Yuka Sugisaki, MD,[a] Hiroki Omori, MD,[a] Hiroaki Matsuura, MD, PhD,[a] Yumi Matsuura, MD,[b] Rika Omote, MD, PhD,[c] Eiki Ichihara, MD, PhD,[a,d] Toshiaki Okada, MD, PhD[a]

[a]*Department of Respiratory Medicine, National Hospital Organization Fukuyama Medical Center, Hiroshima, Japan*
[b]*Department of Pathology, Kawasaki Medical School, Okayama, Japan*
[c]*Department of Diagnostic Pathology, National Hospital Organization Fukuyama Medical Center, Hiroshima, Japan*
[d]*Center for Clinical Oncology, Okayama University Hospital, Okayama, Japan*

Received 20 January 2026; revised 14 March 2026; accepted 23 March 2026
Available online - 28 March 2026

ABSTRACT

Introduction: *KRAS G12C* inhibitors such as sotorasib have improved outcomes in *KRAS G12C*-positive nonsquamous NSCLC; however, the underlying mechanisms remain incompletely understood.

Case: We report a 66-year-old man with advanced lung adenocarcinoma who received multiple lines of systemic therapy and subsequently responded to eighth-line sotorasib but later experienced disease progression. At progression, next-generation sequencing of a metastatic lesion revealed *ERBB3* amplification without additional *KRAS* mutations. Postmortem examination revealed pleomorphic carcinoma.

Conclusion: *ERBB3* amplification may contribute to off-target resistance to sotorasib, and transformation to pleomorphic carcinoma may represent an additional resistance mechanism.

© 2026 The Authors. Published by Elsevier Inc. on behalf of the International Association for the Study of Lung Cancer. This is an open access article under the CC BY-NC-ND license (http://creativecommons.org/licenses/by-nc-nd/4.0/).

Keywords: Case report; *KRAS G12C* mutation; Sotorasib; *ERBB3* amplification; Pleomorphic carcinoma

Introduction

KRAS G12C alterations are found in approximately 1.4% to 4.3% of nonsquamous NSCLC cases in Asia, and the development of targeted therapies has been driven in part by the demonstrated efficacy of sotorasib.[1] However, many aspects of the mechanisms underlying acquired resistance to sotorasib remain unclear.

Herein, we report a case in which a *KRAS G12C* mutation was identified during treatment with sotorasib; *ERBB3* amplification was detected in post-sotorasib resistance specimens; and pleomorphic carcinoma was confirmed at autopsy.

Case Presentation

A 66-year-old man was referred to our hospital after abnormal shadows were detected on chest radiography during routine health screening. Bronchoscopy with transbronchial biopsy (TBB) revealed poorly differentiated lung adenocarcinoma, clinically staged as cT4N3M1c, stage IVB, according to the eighth edition of the Union for International Cancer Control classification. No *EGFR* mutations (cobas EGFR mutation test version

***Corresponding author.**

Address for correspondence: Satoru Senoo, MD, PhD, Department of Respiratory Medicine, National Hospital Organization Fukuyama Medical Center, 4-14-17 Okinogami-cho, Fukuyama, Hiroshima 720-8520, Japan. E-mail: shuttle1126@gmail.com

Cite this article as: Senoo S, Takata K, Matsumori S, et al. Lung adenocarcinoma developing pleomorphic carcinoma with *ERBB3* amplification after acquired resistance to sotorasib: a case report. *JTO Clin Res Rep* 2026;7:100994.

© 2026 The Authors. Published by Elsevier Inc. on behalf of the International Association for the Study of Lung Cancer. This is an open access article under the CC BY-NC-ND license (http://creativecommons.org/licenses/by-nc-nd/4.0/).

ISSN: 2666-3643

https://doi.org/10.1016/j.jtocrr.2026.100994

2), *ALK* expression (D5F3 immunohistochemistry), or *ROS1* fusions (Oncomine DxTT) were detected, and programmed cell death-ligand 1 (PD-L1; 22C3) testing revealed a tumor proportion score of 50%. Comprehensive genomic profiling was not performed at the time of initial diagnosis.

First-line chemotherapy with carboplatin, pemetrexed, and pembrolizumab, followed by maintenance therapy, resulted in a partial response (PR); however, progressive disease (PD) occurred after 12 cycles. Second-line treatment with docetaxel plus ramucirumab also achieved PR, but treatment was discontinued after 3 cycles because of drug-induced rash. Third-line therapy with tegafur/gimeracil/oteracil resulted in stable disease as the best response, but disease progression occurred after 7 cycles. Subsequently, fourth- to seventh-line cytotoxic chemotherapy (amrubicin, nab-paclitaxel, carboplatin plus pemetrexed, and gemcitabine) resulted in PD within a short interval.

Repeat bronchoscopy was performed, and adenocarcinoma cells were identified on lavage cytology. Using a cell-block specimen, a *KRAS G12C* mutation was detected with the Amoy Dx Pan-Lung Cancer polymerase chain reaction panel assay. Sotorasib (960 mg) was initiated as eighth-line therapy 40 months after the initial diagnosis, and the patient achieved a maximum response to PR. Bronchoscopic findings also improved. At 44 months after diagnosis (4 mo after starting sotorasib), PD was observed; however, tumor growth was slow, allowing continuation of therapy beyond PD. At 47 months, palliative radiation therapy (RT, 50 Gy/25 fractions) was administered because of impending obstruction of the right main bronchus due to local tumor enlargement. At 48 months, whole-brain irradiation (30 Gy/10 fractions) was administered to treat the multiple brain metastases, after which sotorasib was resumed. Although treatment was interrupted because of a rash, sotorasib was restarted at 120 mg with systemic corticosteroids (dexamethasone 8 mg, subsequently tapered), and the dose was gradually increased to 360 mg. At 50 months, RT (48 Gy/24 fractions) was administered to treat dysphagia and bleeding caused by hypopharyngeal metastasis. In addition, RT (35 Gy/14 fractions) was administered to the left adrenal gland to alleviate pain associated with the adrenal metastasis. The patient was enrolled in the LC-SCRUM-TRY trial (UMIN000041957). An Oncomine Precision Assay performed on a biopsy sample from the pharyngeal metastasis detected only the *KRAS G12C* mutation (allele frequency, 25.16%) and revealed no secondary *KRAS* alterations; however, *ERBB3* amplification (copy number, 4.05) was identified (Table 1).

Table 1. Results for Oncomine Precision Assay

Gene	Finding
AKT1	Not detected
AKT2	Not detected
AKT3	Not detected
ALK	Not detected
AR	Not detected
ARAF	Not detected
BRAF	Not detected
CD274	Not detected
CDK4	Not detected
CDKN2A	Not detected
CHEK2	Not detected
CTNNB1	Not detected
EGFR	Not detected
ERBB2	Not detected
ERBB3	ERBB3 amplification
ERBB4	Not detected
ESR1	Not detected
FGFR1	Not detected
FGFR2	Not detected
FGFR3	Not detected
FGFR4	Not detected
FLT3	Not detected
GNA11	Not detected
GNAQ	Not detected
GNAS	Not detected
HRAS	Not detected
IDH1	Not detected
IDH2	Not detected
KIT	Not detected
KRAS	KRAS G12C
MAP2K1	Not detected
MAP2K2	Not detected
MET	Not detected
MTOR	Not detected
NRAS	Not detected
NRG1	Not detected
NTRK1	Not detected
NTRK2	Not detected
NTRK3	Not detected
NUTM	Not detected
PDGFRA	Not detected
PIK3CA	Not detected
PTEN	Not detected
RAF1	Not detected
RET	Not detected
ROS1	Not detected
RSPO2	Not detected
RSPO3	Not detected
SMO	Not detected
TP53	Not detected

At 52 months after diagnosis, the patient was admitted because of a decline in performance status. Sotorasib (120 mg), which had been temporarily withheld during RT, was restarted; however, the patient was unable to continue oral intake within 1 week. The patient ultimately died because of disease progression. The clinical time course is found in Figure 1. Autopsy of a specimen obtained from the right lower lobe,

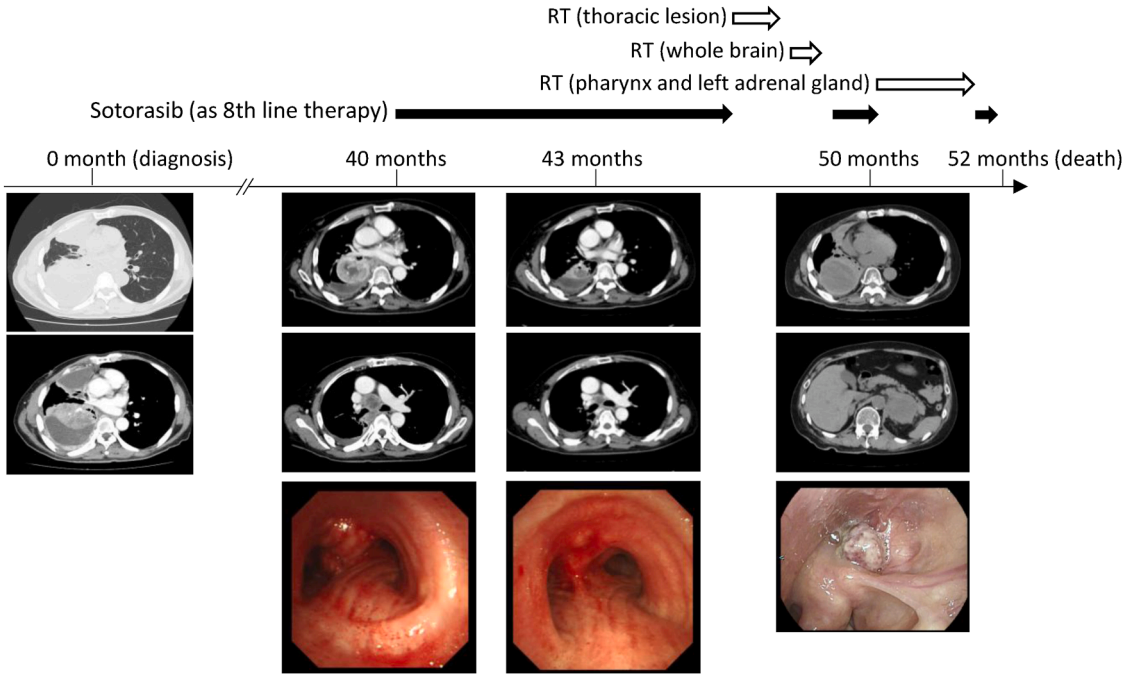

Figure 1. Clinical time course of the case. Timeline revealing systemic treatments, RT, computed tomography images, and bronchoscopic evaluation. Sotorasib was initiated at 40 months, and a PR was achieved at 43 months. Disease progression was observed at 44 months (data not revealed). Further progression, including increased right pleural effusion, left adrenal metastasis, and newly detected pharyngeal metastasis, was noted at 50 months, and the patient died at 52 months. PR, partial response; RT, radiation therapy.

previously confirmed as adenocarcinoma at the initial diagnosis and corresponding to the primary lesion, revealed a tumor with extensive necrosis and histologic features consistent with pleomorphic carcinoma, comprising giant cell carcinoma and poorly differentiated adenocarcinoma components (Fig. 2).

Discussion

Herein, we report a case of lung adenocarcinoma with pleomorphic carcinoma histology and *ERBB3* amplification identified at the time of acquired resistance to sotorasib. This case highlights *ERBB3* amplification and histologic transformation to pleomorphic carcinoma as potential mechanisms underlying acquired resistance to sotorasib.

The mechanisms of acquired resistance to sotorasib are broadly categorized into on-target secondary *KRAS* mutations and off-target activation of bypass signaling pathways. On-target mechanisms include acquired secondary *KRAS* mutations such as *G12D/R/V/W*, *G13D*, *Q61H*, *R68S*, *H95D/Q/R*, and *Y96C*. Reported off-target mechanisms include gene amplification (e.g., *MET*), activating mutations (e.g., *NRAS*, *BRAF*, *MAP2K1*, *RET*), acquired fusions (*ALK*, *RET*, *BRAF*, *RAF1*, *FGFR3*), and loss-of-function alterations in *NF1* and *PTEN*. Furthermore, histologic transformation, including transformation to squamous cell carcinoma, has been described as a distinct mechanism of resistance.[1–3] Subsequent molecular profiling in patients enrolled in the pivotal CodeBreaK 100 and 200 studies demonstrated the emergence of additional genomic events at progression, with *TP53*, *MET* (mainly amplifications), and *EGFR* (mainly amplifications) among the most frequently observed alterations.[4] Within the ERBB family, *ERBB2* amplification is recognized as a bypass mechanism,[2] whereas *ERBB3* alterations have not previously been reported as a mechanism of sotorasib resistance.

In our patient, next-generation sequencing of a clinically resistant lesion revealed *ERBB3* amplification without additional *KRAS* alterations. Because *ERBB3* was the only newly detected genomic abnormality, we considered the possibility that ERBB3-mediated signaling contributed to resistance. Whether the amplification was preexisting or acquired remains unknown, as ERBB3 status could not be assessed in the baseline specimen.

ERBB3 plays a distinct role in lung cancer biology. Although it has limited intrinsic kinase activity, heterodimerization with EGFR or ERBB2 activates downstream PI3K/AKT and MAPK signaling pathways and has been implicated in therapeutic resistance across multiple malignancies.[5,6] In NSCLC, particularly adenocarcinoma, *ERBB3* expression has been documented and functionally linked to receptor tyrosine

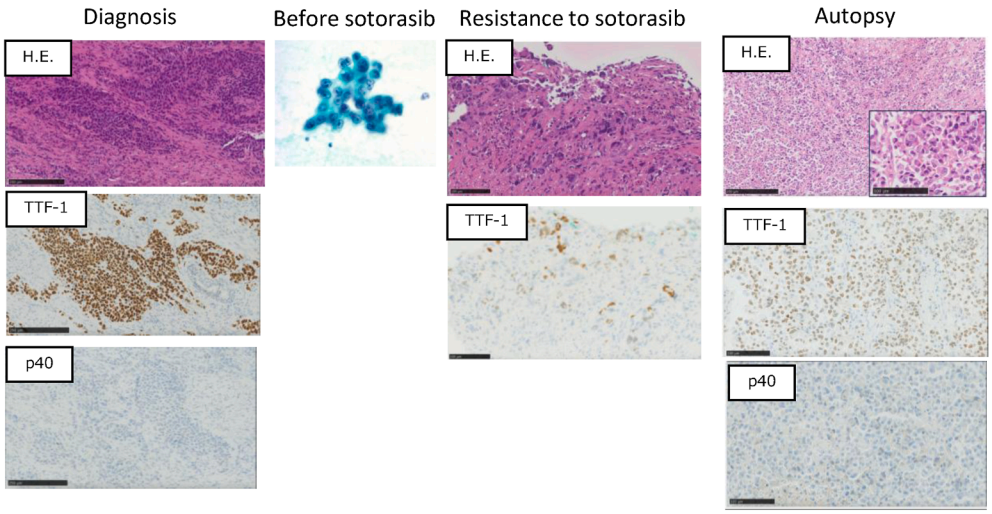

Cytology /Histology	Adenocarcinoma	Adenocarcinoma	Adenocarcinoma	Pleomorphic carcinoma
EGFR	(-)	(-)	(-)	ND
ALK	(-)	(-)	(-)	ND
ROS1	(-)	(-)	(-)	ND
KRAS	ND	G12C	G12C	ND
ERBB3	ND	ND	amplification	ND

Figure 2. Cytologic, histologic, and genomic findings at baseline and at acquired resistance. The patient was initially diagnosed with poorly differentiated adenocarcinoma based on a TBB. Neither *KRAS* status nor comprehensive next-generation sequencing-based profiling was evaluated at diagnosis; however, *KRAS G12C* positivity was later confirmed by cytology. A specimen obtained from the pharyngeal metastasis after the development of sotorasib resistance revealed persistent *KRAS G12C* without secondary *KRAS* mutations, along with a newly identified *ERBB3* amplification. Autopsy revealed a pleomorphic carcinoma composed of giant cell carcinoma and poorly differentiated adenocarcinoma components. H.E., hematoxylin and eosin staining; TBB, transbronchial biopsy; TTF-1, thyroid transcription factor-1; ND, not determined.

kinase–mediated survival signaling.[5,6] These characteristics support a biologically plausible bypass mechanism in which *ERBB3* amplification could restore downstream pathway activity despite *KRAS G12C* inhibition. Moreover, *ERBB3* amplification has been reported in a subset of *EGFR*-mutant lung cancers, and ERBB3-targeted agents such as patritumab deruxtecan are under clinical investigation in this setting.[5,6] Collectively, these observations suggest that ERBB3 may represent a potential therapeutic vulnerability beyond *EGFR*-mutant disease, potentially including KRAS-driven lung cancers. Autopsy revealed pleomorphic carcinoma composed of giant cells and poorly differentiated adenocarcinoma components. Histologic transformation during treatment is well documented in *EGFR*-mutant lung cancer and is thought to reflect dedifferentiation under therapeutic pressure.[7] Reports of pleomorphic transformation in *KRAS*-mutated lung cancer are extremely rare, with only one published case involving *KRAS G12C*; however, the case described sarcomatoid carcinoma rather than pleomorphic carcinoma, and no prior report has clearly documented transformation exclusively to pleomorphic carcinoma.[8] Although we cannot exclude the possibility that pleomorphic components were present at baseline but not captured by TBB, the marked morphologic changes observed at autopsy suggest a treatment-related evolution.

This report has several limitations. First, this is a single-case observation without functional validation, and therefore, a causal relationship between *ERBB3* amplification and resistance to sotorasib cannot be established. Second, comprehensive genomic profiling was not performed at baseline, and *ERBB3* amplification may have been present before sotorasib exposure. Third, the initial diagnosis was based on a TBB specimen, which may not have captured a giant cell component.

The coexistence of *ERBB3* amplification and pleomorphic morphology raises the hypothesis that *ERBB3*-driven signaling may facilitate dedifferentiation; however, the current evidence is insufficient to establish a causal relationship. Further accumulation of similar cases is required.

Conclusion

ERBB3 amplification and transformation to pleomorphic carcinoma may represent potential

mechanisms of resistance to *KRAS G12C*-targeted therapy. This case illustrates the biological heterogeneity of *KRAS G12C*-positive NSCLC and underscores the need for molecular reevaluation at the time of disease progression. Repeat biopsy and genomic analysis may help identify patient-specific resistance mechanisms and guide the development of novel therapeutic strategies, including combination approaches targeting parallel signaling pathways or ERBB3-directed therapies.

CRediT Authorship Contribution Statement

Satoru Senoo: Conceptualization, Data curation, Investigation, Visualization, Writing – original draft.

Kohei Takata: Writing – review & editing.

Shunsuke Matsumori: Writing – review & editing.

Takahiro Baba: Writing – review & editing.

Yuka Sugisaki: Writing – review & editing.

Hiroki Omori: Writing – review & editing.

Hiroaki Matsuura: Writing – review & editing, Visualization.

Yumi Matsuura: Investigation, Resources, Writing – review & editing.

Rika Omote: Investigation, Resources, Writing – review & editing.

Eiki Ichihara: Supervision, Writing – review & editing.

Toshiaki Okada: Supervision, Writing – review & editing.

Declaration of Generative AI and AI-Assisted Technologies in the Writing Process

During the preparation of this paper, the authors used ChatGPT for language editing to improve readability. After using this tool, the authors reviewed and edited the content as needed and take full responsibility for the content of the publication.

Acknowledgment

The authors extend their deepest gratitude to the LC-SCRUM-TRY Secretariat for conducting these analyses. Written informed consent was obtained from the patient.

References

1. Tenekeci AK, Unal AA, Ceylan F, Nahit Sendur MA. An updated overview of K-RAS G12C inhibitors in advanced stage non-small cell lung cancer. *Future Oncol*. 2024;20:3019–3038.
2. Chour A, Toffart AC, Berton E, Duruisseaux M. Mechanisms of resistance to KRASG12C inhibitors in KRASG12C-mutated non-small cell lung cancer. *Front Oncol*. 2024;14:1328728.
3. Awad MM, Liu S, Rybkin II, et al. Acquired resistance to KRASG12C inhibition in cancer. *N Engl J Med*. 2021;384:2382–2393.
4. Skoulidis F, Li BT, de Langen AJ, et al. Molecular determinants of sotorasib clinical efficacy in KRASG12C-mutated non-small-cell lung cancer. *Nat Med*. 2025;31:2755–2767.
5. Uliano J, Corvaja C, Curigliano G, Tarantino P. Targeting HER3 for cancer treatment: a new horizon for an old target. *ESMO Open*. 2023;8:100790.
6. Chen Y, Lu A, Hu Z, Li J, Lu J. ERBB3 targeting: a promising approach to overcoming cancer therapeutic resistance. *Cancer Lett*. 2024;599:217146.
7. Pathak R, Villaflor VM. Histologic transformation in EGFR-mutant lung adenocarcinomas: mechanisms and therapeutic implications. *Cancers (Basel)*. 2021;13:4641.
8. Pang L, Zhuang W, Huang Y, et al. Rare transformation from lung adenocarcinoma to sarcomatoid carcinoma mediates resistance to inhibitors targeting different driver oncogenes. *J Natl Cancer Cent*. 2024;5:75–81.