Asia-Pacific Journal of Sports Medicine, Arthroscopy, Rehabilitation and Technology 46 (2026) 24–30

Contents lists available at ScienceDirect

Asia-Pacific Journal of Sports Medicine, Arthroscopy, Rehabilitation and Technology

journal homepage: www.ap-smart.com

Technical Note

Pullout repair combined with double-plate fixation via inverted V-shaped high tibial osteotomy for medial meniscus posterior root tears with severe varus tibial deformity

Toshiki Kohara [a,b], Yuki Okazaki [b,*], Takayuki Furumatsu [c], Yusuke Yokoyama [b], Takaaki Hiranaka [b], Koki Kawada [b], Tomonori Tetsunaga [b,d], Toshifumi Ozaki [a,b]

[a] Department of Orthopaedic Surgery, Section of Medicine, Division of Medicine, Dentistry and Pharmaceutical Sciences, Graduate School of Medicine, Okayama University, Okayama, Japan
[b] Department of Orthopaedic Surgery, Faculty of Medicine, Dentistry and Pharmaceutical Sciences, Okayama University, Okayama, Japan
[c] Department of Orthopedic Surgery, Japanese Red Cross Okayama Hospital, Okayama, Japan
[d] Department of Musculoskeletal Health Promotion, Faculty of Medicine, Dentistry and Pharmaceutical Sciences, Okayama University, Okayama, Japan

ARTICLE INFO

Keywords:
Double-plate fixation
High tibial osteotomy
Inverted V-Shaped osteotomy
Medial meniscus posterior root tear
Transtibial pullout repair

ABSTRACT

Medial meniscus (MM) posterior root tears (PRTs) disrupt hoop stress transmission and accelerate the progression of medial compartment osteoarthritis. High tibial osteotomy (HTO) combined with transtibial pullout repair is indicated in selected patients with a high body mass index, severe varus malalignment, or high functional demands. Although medial open-wedge HTO (MOWHTO) is widely performed, correction angles exceeding approximately 12° may compromise mechanical stability and increase the risk of lateral hinge fracture and delayed union. In patients with predominantly tibial-based deformity and a predicted postoperative medial proximal tibial angle (MPTA) of less than 95°, double-level osteotomy is generally unnecessary; in such circumstances, a closing-wedge strategy is biomechanically appropriate. However, conventional lateral closing-wedge or hybrid closing-wedge HTO techniques reduce medial proximal tibial bone stock, leaving insufficient cortical bone to safely accommodate transtibial pullout repair for MMPRTs. Therefore, when HTO is performed in conjunction with MMPRT repair, preservation of adequate medial bone stock is essential. To our knowledge, no previous studies have described a technique specifically designed to address this structural requirement. This technical note describes a surgical technique combining transtibial pullout repair for MMPRTs with inverted V-shaped HTO (iV-HTO), a closing-wedge–based osteotomy that preserves medial cortical bone stock while permitting substantial angular correction. The medial approach required for pullout repair provides two additional advantages: independent tibial tunnel placement with reduced risk of interference from lateral plate screws second straightforward augmentation with an additional medial plate when indicated. The supplementary medial plate reinforces the weakened medial cortex, enhances construct stability, and may facilitate earlier weight-bearing while promoting reliable osseous union. The indications, surgical technique, technical considerations, and potential advantages of combining iV-HTO with transtibial pullout repair for MMPRTs in patients with severe tibial varus deformity are also presented.

1. Introduction

Medial meniscus (MM) posterior root tears (PRTs) typically occur in middle-aged women during routine activities such as walking, descending stairs, or knee twisting.[1,2] The MM posterior root connects the meniscus to the tibial plateau and plays a critical role in converting axial load into circumferential hoop stress.[3] Following an MMPRT, this load distribution mechanism is lost, resulting in peak contact pressures comparable to those observed after a total medial meniscectomy,[3] which can rapidly accelerate the progression of knee osteoarthritis (OA).[4] Transtibial pullout repair is recommended in the acute phase of MMPRT in patients with mild varus alignment. However, pullout repair alone does not completely prevent the progression of medial meniscus extrusion (MME),[5] and long-term clinical outcomes remain uncertain,

* Corresponding author.
E-mail address: yokazaki.okayama@gmail.com (Y. Okazaki).

https://doi.org/10.1016/j.asmart.2026.08.001
Received 23 February 2026; Received in revised form 19 June 2026; Accepted 7 August 2026
Available online 19 August 2026
2214-6873/© 2026 Published by Elsevier B.V. on behalf of Asia-Pacific Knee, Arthroscopy, Arthroplasty, Shoulder and Sports Medicine Society (APKASS). This is an open access article under the CC BY-NC-ND license (http://creativecommons.org/licenses/by-nc-nd/4.0/).

although some studies have reported favorable mid-to long-term results.[6] Outcomes may be less favorable in patients with risk factors for OA progression, including high body mass index, marked varus alignment, and high activity levels. Therefore, in chronic presentations or in the presence of severe varus deformity, obesity, or high activity demands, alternative surgical strategies such as high tibial osteotomy (HTO) or unicompartmental knee arthroplasty should be considered.

HTO has demonstrated favorable clinical outcomes and may also modulate the intra-articular biological environment.[7] Several short-term studies suggest that concurrent MMPRT repair may not be necessary when performing HTO[8–10]. However, other studies have reported that combining HTO with MMPRT repair may enhance cartilage preservation and improve return-to-sport outcomes.[11,12] In addition, biomechanical studies have indicated that the combined procedure improves contact pressure distribution within the medial compartment.[13] Therefore, the addition of MMPRT pullout repair to HTO may more effectively restore load sharing and meniscal hoop stress function, potentially delaying OA progression.

Among HTO techniques, medial open-wedge HTO (OWHTO) is the most widely performed. Although postoperative progression of patellofemoral joint changes have been reported, these changes do not appear to significantly influence clinical outcomes.[14,15] However, when a correction angle requiring >12° is required or when the predicted postoperative medial proximal tibial angle (MPTA) exceeds 95°, closing-wedge HTO (CWHTO) or double-level osteotomy (DLO) should be considered. Several CWHTO techniques, including hybrid CWHTO and inverted V-shaped HTO (iV-HTO), have been developed and have demonstrated favorable clinical and radiographic outcomes. iV-HTO offers several advantages. Preservation of the hinge reduces intraoperative instability and facilitates bony healing. In addition, positioning the hinge near the center of rotation of angulation (CORA) minimizes limb length discrepancy.[16] Furthermore, a distally directed medial condylar cut enables the creation of pullout bone tunnels in the proximal segment, which is particularly advantageous for concurrent MMPRT repair.

This technical note describes a surgical technique that combines MMPRT pullout repair with iV-HTO using double-plate fixation.

2. Surgical technique

2.1. Inclusion and exclusion criteria

- Patients with acute or chronic MMPRT
- Patients with medial compartment osteoarthritis and a proximal tibial deformity requiring a coronal correction of ≥12° on preoperative planning
- Patients with a predicted MPTA of ≤95°, with DLO considered when greater correction is required
- Patients with subchondral insufficiency fracture of the knee (grade ≤3) and Kellgren–Lawrence classification grade ≤3
- Patients with patellofemoral osteoarthritis regardless of radiographic grade, provided that symptoms are not severe
- Patients who have provided informed consent at the time of initial surgery for implant removal if plate-related symptoms persist postoperatively

2.2. Preoperative planning

Preoperative planning was performed using standing full-length anteroposterior radiographs of the lower limbs.[16] The weight-bearing line was targeted to pass through 60%–65% of the tibial plateau width, in accordance with the consensus of the European Society of Sports Traumatology, Knee Surgery and Arthroscopy.[17]

2.3. Arthroscopy, pie-crusting, two simple stitches, and suture pullout

Under general anesthesia, the patient was placed in the supine position, and a nonsterile tourniquet was applied. A 5-cm skin incision was made over the anteromedial tibia, and only the anterior fibers of the superficial medial collateral ligament (MCL) were minimally elevated. Standard anteromedial and anterolateral portals were created to inspect the cartilage and meniscus (Fig. 1). After confirmation of the MMPRT (Fig. 1a), MCL pie-crusting was performed when the joint space was narrow. Two simple stitches using ultra-high-molecular-weight polyethylene tape were placed through the torn root (Fig. 1b).

A tibial tunnel was created at the anatomical root attachment site using a posterior root guide (Smith & Nephew, London, UK). To avoid interference with the MCL and the planned medial plate, the tunnel was positioned slightly toward the tibial tubercle and drilled at a shallow angle (approximately 30°). The sutures were retrieved through the tunnel using a suture retriever and looped shuttle technique, and all sutures were pulled out (Fig. 1c).

2.4. Fibular osteotomy

Meticulous surgical technique is essential during this step.[18] A 5-cm longitudinal incision was made along the posterolateral midshaft of the fibula, with careful attention to avoid injury to the superficial peroneal nerve. After incising the fascia, the peroneus longus was detached from the intermuscular septum and retracted anteriorly. The periosteum was circumferentially elevated, and curved elevators were placed anteriorly and posteriorly along the fibular cortex to protect the surrounding neurovascular structures. During this step, the elevators were kept in close contact with the fibular cortex, particularly along its anterior and medial aspects, to avoid injury to the deep peroneal nerve and anterior tibial vessels. The fibula was then osteotomized obliquely at approximately 30° to its longitudinal axis to maximize the bone contact area.

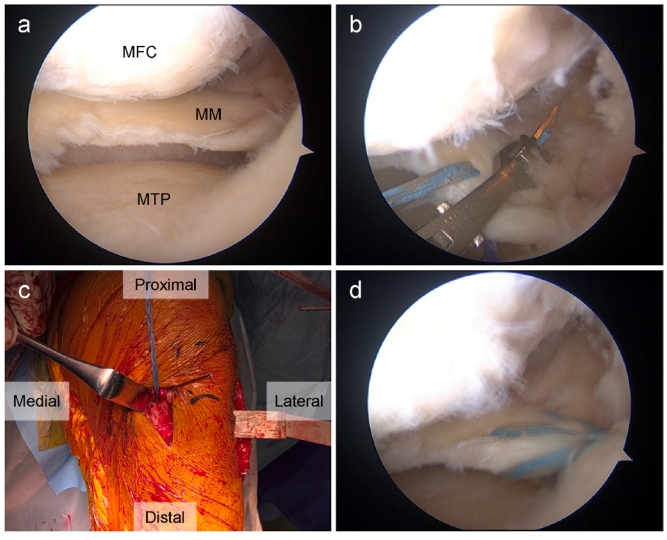

Fig. 1. Intraoperative arthroscopic and clinical images.
(a) Complete tear of the medial meniscus (MM) posterior root.
(b) Two simple stitches are placed in the torn MM posterior root using a knee Scorpion and UHMWPE tape.
(c) The pullout sutures are passed through the tibial bone tunnel and left outside.
(d) The repaired MM posterior root after pullout repair.
MFC, medial femoral condyle; MM, medial meniscus; MTP, medial tibial plateau.

2.5. Lateral exposure and tibial osteotomy

With the knee extended, a 10-cm lateral incision was made over the anterolateral aspect of the tibia. As the guide pins were required to be inserted through the osteotomy guide, a mini-incision was not feasible. The tibialis anterior (TA) fascia was incised, leaving a 1-cm cuff for later repair. The TA and iliotibial band (ITB) were elevated from Gerdy's tubercle, and the ITB was incised proximally and elevated to allow the ascending cut. The periosteum was elevated from the posterolateral toward the posteromedial tibia to facilitate safe retractor placement. A 2.0-mm Kirschner wire (KW) was inserted at the hinge point (20–25 mm distal to the joint line through the medial intercondylar eminence). The Wedge Cutting Guide (OsferionBiomaterials Corp., Tokyo, Japan) was attached, and two 2.0-mm KWs were inserted proximally and two distally to achieve the preplanned correction angle (Fig. 2a and b). After removal of the guide, an ascending cut for the lateral tibial tuberosity was made 12 mm posterior to the tibial tuberosity, and a closing wedge osteotomy was performed between the four KWs. After protecting the posterior tibia using a retractor, the posterior cortex was completely cut using a reciprocating saw. The bony wedge was removed and morselized for grafting to the medial gap.

2.6. Medial osteotomy: Exposure at the pullout step

The Parallel Drill Guide (OsferionBiomaterials Corp.) was positioned to avoid the previously created pullout tunnel and temporarily secured with a 2.0-mm KW. The knee was flexed to increase the distance from the popliteal artery. Using the guide, a 2.0-mm KW was advanced to penetrate both the anterior and posterior cortices (Fig. 2c and d). To reduce the risk of hinge fracture, the area immediately medial to the hinge pin was left unperforated. The osteotomy was completed using a 15–20-mm osteotome. A 2.0-mm KW was inserted lateral to the hinge point to protect the hinge. The knee was returned to extension, the ascending cut of the remaining medial tibial tuberosity was completed, and a valgus force was manually applied to close the lateral side. The osteotomy site was temporarily stabilized with a 2.0-mm KW.

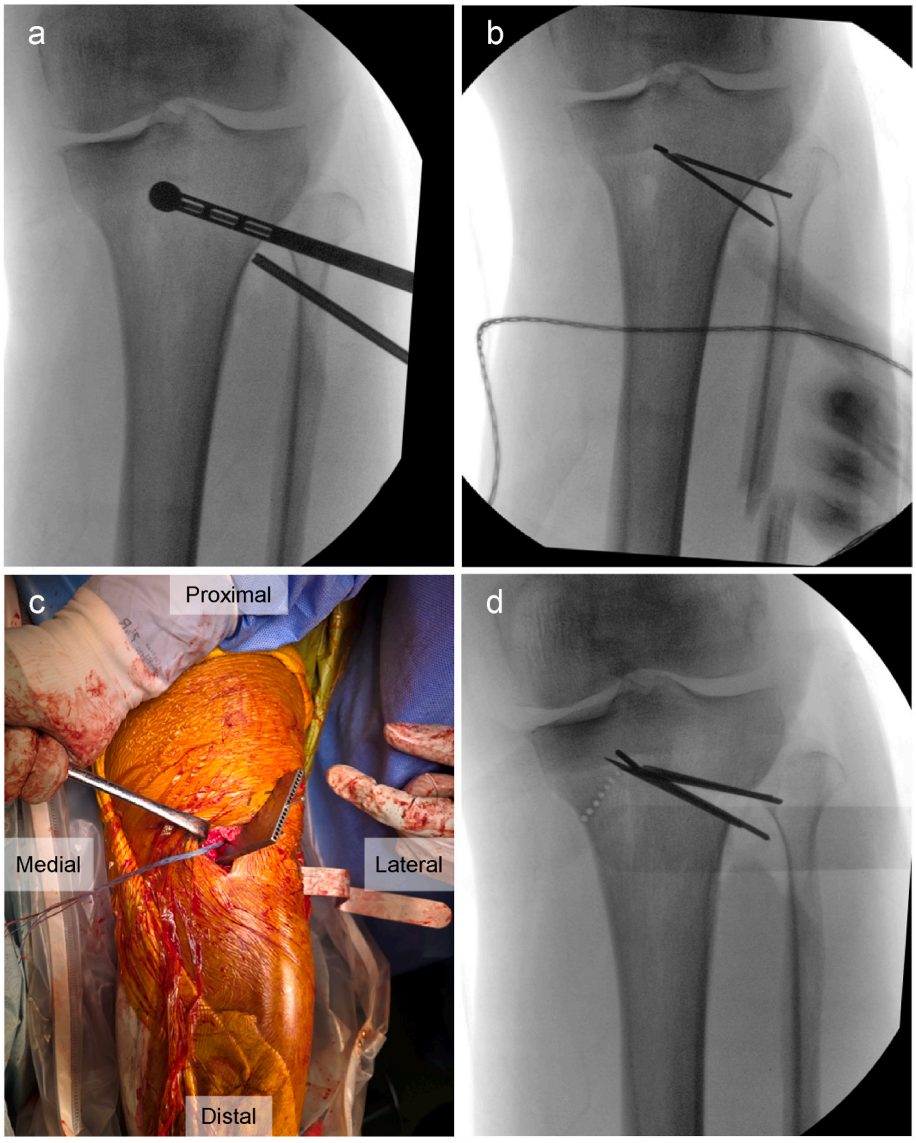

Fig. 2. Intraoperative fluoroscopic and clinical images.
(a and b) A hinge wire is inserted at the medial tibial eminence, 20–25 mm distal to the joint line, aiming toward the center of rotation of angulation. Two 2.0-mm K-wires are inserted proximally and distally through the Wedge Cutting Guide to achieve the preoperatively planned correction angle.
(c and d) The Parallel Drill Guide is positioned to avoid the pullout tunnel, and drilling of the anterior and posterior cortices of the medial osteotomy site is performed using a 2.0-mm K-wire. This is performed with the knee-flexed to increase the distance from the popliteal artery.

2.7. Lateral plate fixation

To prevent interference between the pullout sutures and screws, a 4.0-mm cannulated drill was reinserted into the bone tunnel as a protective sleeve (Fig. 3a and b). The lateral plate was positioned at the optimal site, with interference typically occurring at hole B (the central screw among the three proximal screws). When the screw trajectory conflicted with the sleeve, the screw was advanced up to, but not beyond, the point of contact. After securing the proximal screws, a second distal cortical screw was inserted and tightened to draw the distal segment toward the plate while adjusting the MPTA according to the preoperative plan (Fig. 3c). Once satisfactory alignment was achieved, locking screws were inserted into the remaining holes, and the cortical screw was subsequently replaced with a locking screw.

2.8. Medial plate fixation and pullout suture fixation

The medial plate was positioned over the pes anserinus to avoid interference with the bone tunnel and MCL and was provisionally fixed. Screw lengths were selected to avoid contact with the protective sleeve, and at least three of the four distal holes were engaged.

Subsequently, the 4.0-mm cannulated drill was removed. The pullout sutures were secured at 30° of knee flexion under 20 N of tension using a spring tensioner[19] and a 5.0-mm bioabsorbable screw (Smith & Nephew) (Fig. 1d). The sutures were then tied around the medial plate to prevent proximal migration of the construct. Finally, the medial osteotomy gap was firmly packed with morselized bone harvested from the lateral wedge.

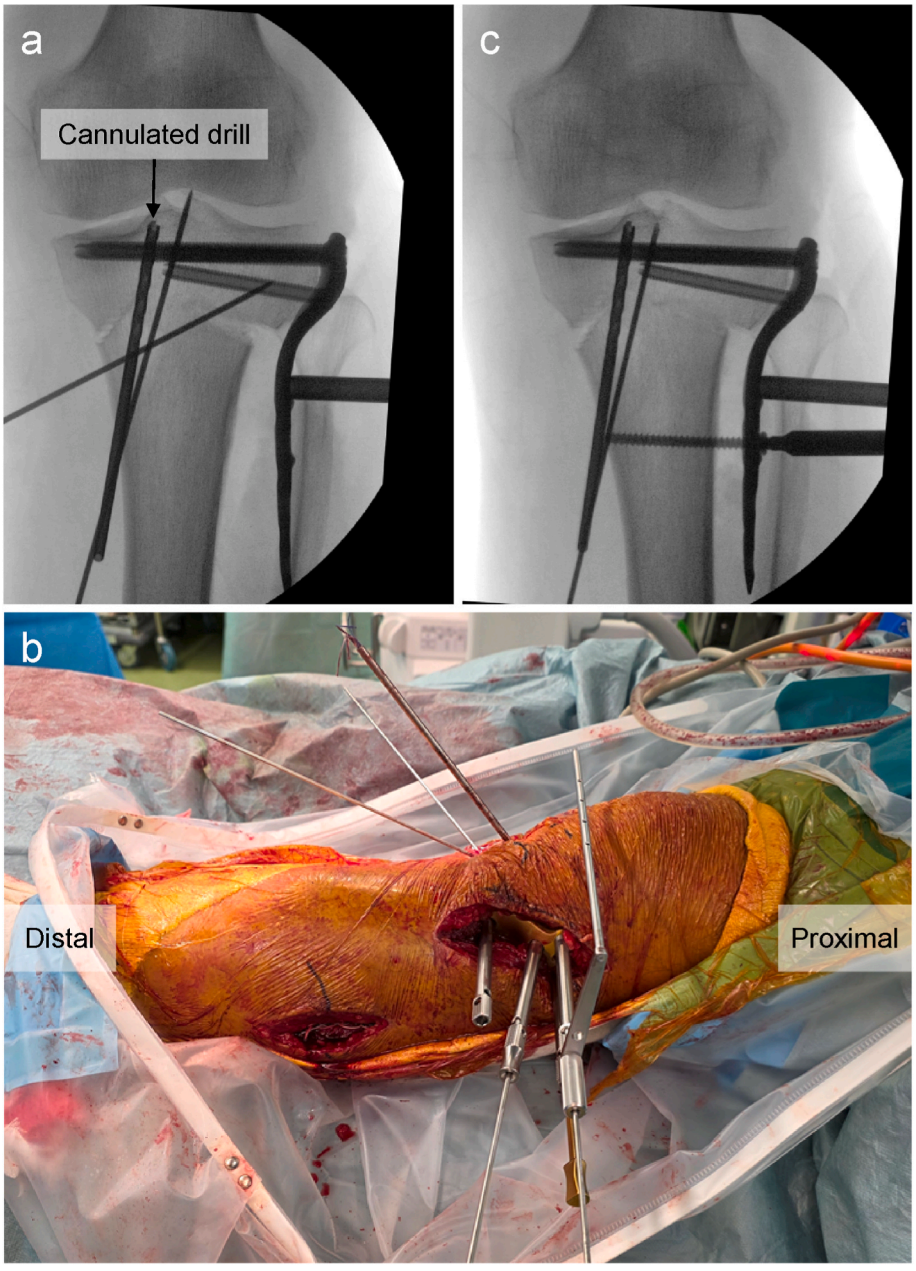

Fig. 3. Intraoperative fluoroscopic and clinical images.
(a) A 4.0-mm cannulated drill is reinserted into the pullout tunnel as a protective sleeve during drilling for the screws of the lateral plate.
(b) Clinical photograph showing reinsertion of the 4.0-mm cannulated drill as a protective sleeve.
(c) After fixation of the proximal screws, a cortical screw is inserted into the second distal hole to compress the distal segment to the plate.

2.9. Fibular fixation and closure

If displacement at the fibular osteotomy site was minimal, fixation was performed using ligation.[20] When significant displacement persisted (typically when the osteotomy was performed slightly proximal to the center of the fibular shaft), approximately 5 mm of the fibular bone was resected and a 2.0-mm KW was inserted as an intramedullary pin (Fig. 4a and b).

The TA fascia was repaired but its distal end was left partially open to reduce the risk of compartment syndrome. Drains were placed in the fibular osteotomy site and anterior compartment to reduce pressure and the risk of peroneal nerve palsy. The medial wound was then closed in the standard manner (Fig. 4c and d).

2.10. Postoperative rehabilitation

- Postoperative day 1: range of motion (ROM) 0°–30°; partial weight bearing (PWB) at 25 kg
- Postoperative week 1: ROM 0–60°; PWB at 50 kg
- Postoperative week 2: ROM 0–90°; PWB at 75 kg
- Postoperative week 3: weight bearing up to 100 kg
- Postoperative week 4: ROM 0°–120°; full weight bearing (FWB)

At 3 months postoperatively, magnetic resonance imaging was

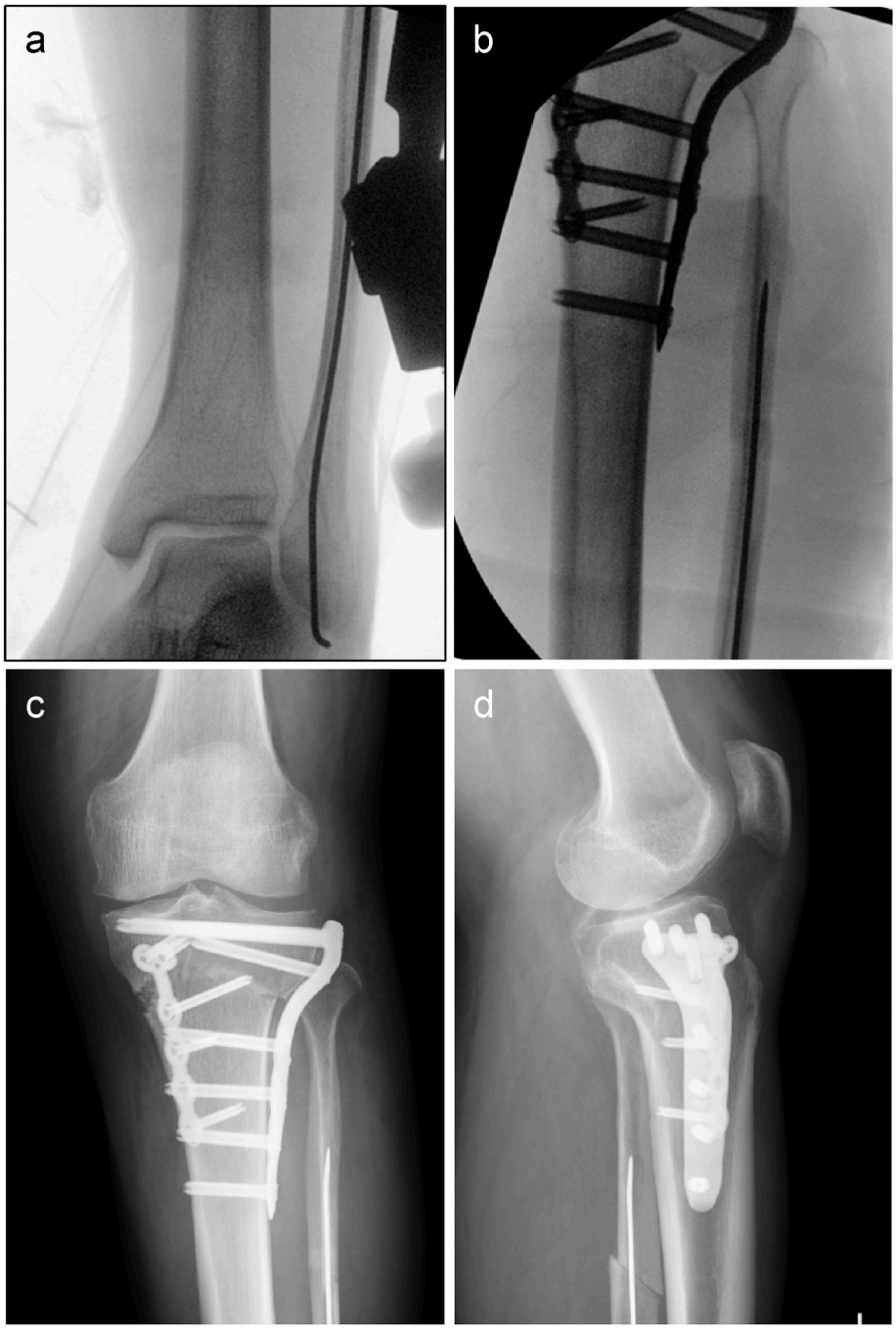

Fig. 4. Intraoperative fluoroscopic images and postoperative radiographs.
(a and b) Robust fixation of the fibula is obtained after intramedullary K-wire fixation.
(c and d) Postoperative radiographs: **(c)** anteroposterior view; **(d)** lateral view.

obtained. If continuity of the repaired MM posterior root was confirmed, a gradual return to sports was permitted, with progression to contact sports from 6 months.

2.11. Advantages and disadvantages

2.11.1. Advantages

- Preservation of the hinge reduces intraoperative instability
- Compression at the closed wedge and grafting of resected bone promote faster union.
- Positioning of the hinge near the CORA minimizes limb length discrepancy.
- The risk of patella baja is reduced, with potential benefit to patellofemoral joint mechanics.
- Concomitant meniscal repair reduces medial compartment joint pressure and improves long-term outcomes.
- PTS has been reported to decrease after iv-HTO[21], which may reduce strain on the anterior cruciate ligament.

2.12. Disadvantages

- The overall procedure is technically demanding.
- Meticulous surgical technique is required, as complications such as common peroneal nerve injury, although uncommon, can be severe.
- Screw–tunnel interference is unavoidable; screw length adjustment and/or minor plate repositioning may be necessary, and the most proximal screw (often the B-hole) may not reach the medial cortex.
- In muscular patients, fibular osteotomy may result in marked displacement.
- Intramedullary wire fixation may be required to achieve reliable union at the fibular osteotomy site when residual displacement or instability persists after ligation.

3. Discussion

Several studies have reported favorable outcomes with the combination of OWHTO or distal tuberosity osteotomy and MMPRT transtibial pullout repair[22–24]. However, in patients with marked varus deformity requiring $\geq 12^{\circ}$ of coronal correction, CWHTO or DLO generally represent the preferred corrective options. A recognized limitation of CWHTO is limb shortening, whereas DLO is more invasive and is associated with greater blood loss and longer operative times. Consequently, tibial-side correction alone is preferable when adequate alignment can be achieved.

Compared with hybrid CWHTO, iV-HTO offers the distinct advantage of preserving a larger segment of medial proximal tibial bone, thereby facilitating more reliable creation of the bone aperture required for transtibial pullout repair. In addition, positioning the hinge near the CORA minimizes limb length changes while allowing substantial angular correction and exerting minimal influence on patellofemoral joint mechanics.

The evidence supporting the combination of HTO and pullout repair remains limited and controversial. Some studies have reported favorable effects of concomitant pullout repair on clinical outcomes, MM extrusion, medial joint space width, cartilage regeneration, and return-to-sports rates.[11,12,25] However, other investigations[8–10] failed to demonstrate significant differences between HTO performed with and without pullout repair. Comparative studies have demonstrated lower Knee injury and Osteoarthritis Outcome Score and greater progression of MME in patients undergoing HTO for MMPRT without pullout repair than in those undergoing HTO for knees without MMPRT. These findings suggest that failure to address MMPRT, even after HTO, may accelerate the progression of medial compartment OA owing to persistent loss of the meniscal hoop stress mechanism.[26]

Fibular osteotomy is an essential component of lateral closing-wedge HTO. Several fixation methods have been described, including trimming of the osteotomy edges, fixation with high-strength sutures, plate fixation, and intramedullary fixation using a KW. Compared with fibular osteotomy followed by ligation, fibular osteotomy alone has been associated with a higher nonunion rate, which may result in lateral leg pain and tenderness at the osteotomy site during ambulation.[20] However, suture fixation alone may not provide sufficient stability, particularly in patients with substantial muscle mass or those requiring large valgus corrections. Although plate fixation provides stability, it is associated with greater invasiveness and implant-related irritation. By contrast, intramedullary KW fixation is minimally invasive and provides adequate stability. Following valgus correction, overlap of the proximal and distal fibular segments typically occurs, requiring limited resection of the fibular ends according to the degree of overlap. Precise measurement is generally unnecessary, and the procedure is technically straightforward. Once stabilized, the fibular osteotomy site becomes more secure, which may reduce postoperative pain and decrease the risk of peroneal nerve palsy. Despite these potential advantages, further studies with long-term follow-up are needed to establish the clinical efficacy and durability of this technique.

Ethics approval and consent to participate

Written informed consent was obtained from the patient prior to inclusion in this report.

The consent included permission to publish clinical photographs and imaging studies. The ethics approval number for this study is 2410-005

Funding sources

This research did not receive any specific grant from funding agencies in the public, commercial, or not-for-profit sectors.

Conflicts of interest

The authors declare that they have no conflicts of interest relevant to this article.

Acknowledgements

The authors would like to thank Editage (www.editage.jp) for providing English language editing support.

References

1. Furumatsu T, Okazaki Y, Okazaki Y, et al. Injury patterns of medial meniscus posterior root tears. *Orthop Traumatol Surg Res*. Feb 2019;105(1):107–111. https://doi.org/10.1016/j.otsr.2018.10.001.
2. Kamatsuki Y, Furumatsu T, Hiranaka T, et al. Epidemiological features of acute medial meniscus posterior root tears. *Int Orthop*. Oct 2023;47(10):2537–2545. https://doi.org/10.1007/s00264-023-05848-0.
3. Allaire R, Muriuki M, Gilbertson L, Harner CD. Biomechanical consequences of a tear of the posterior root of the medial meniscus. Similar to total meniscectomy. *J Bone Joint Surg Am*. Sep 2008;90(9):1922–1931. https://doi.org/10.2106/jbjs.G.00748.
4. Krych AJ, Lamba A, Wang AS, et al. Nonoperative management of degenerative medial Meniscus posterior root tears: poor outcomes at a minimum 10-Year Follow-up. *Am J Sports Med*. Aug 2023;51(10):2603–2607. https://doi.org/10.1177/03635465231185132.
5. Kawada K, Furumatsu T, Yokoyama Y, Higashihara N, Tamura M, Ozaki T. Longitudinal changes in medial meniscus extrusion and clinical outcomes following pullout repair for medial meniscus posterior root tears: a 3-year evaluation. *Eur J Orthop Surg Traumatol*. May 2024;34(4):2021–2029. https://doi.org/10.1007/s00590-024-03889-8.
6. Chung KS, Ha JK, Ra HJ, Yu WJ, Kim JG. Root repair versus partial meniscectomy for medial Meniscus posterior root tears: Comparison of long-term survivorship and clinical outcomes at minimum 10-Year Follow-up. *Am J Sports Med*. Jul 2020;48(8):1937–1944. https://doi.org/10.1177/0363546520920561.
7. Yoshida S, Nishitani K, Yoshitomi H, et al. Knee alignment correction by high tibial osteotomy reduces symptoms and synovial inflammation in knee osteoarthritis accompanied by macrophage phenotypic change from M1 to M2. *Arthritis Rheumatol*. Jun 2023;75(6):950–960. https://doi.org/10.1002/art.42424.

8. Cortina G, Antuofermo SM, Papalia GF, et al. Limited clinical benefit of medial meniscus posterior root repair combined with high tibial osteotomy in varus knee osteoarthritis: a systematic review and meta-analysis. *J Exp Orthop*. Jul 2025;12(3), e70431. https://doi.org/10.1002/jeo2.70431.
9. Dong C, Kong L, Niu Y, Dong J. Repairing the medial meniscus posterior root during open-wedge high tibial osteotomy does not significantly affect clinical outcomes. *Front Surg*. 2025;12, 1672154. https://doi.org/10.3389/fsurg.2025.1672154.
10. Kyun-Ho S, Hyun-Jae R, Ki-Mo J, Seung-Beom H. Effect of concurrent repair of medial meniscal posterior root tears during high tibial osteotomy for medial osteoarthritis during short-term follow-up: a systematic review and meta-analysis. *BMC Muscoskelet Disord*. Jul 15 2021;22(1):623. https://doi.org/10.1186/s12891-021-04499-9.
11. Guo H, Li Q, Zhang Z, et al. Better clinical outcomes and return to sport rates with additional medial meniscus root tear repair in high tibial osteotomy for medial compartmental knee osteoarthritis. *Knee Surg Sports Traumatol Arthrosc*. Jul 2024;32(7):1753–1765. https://doi.org/10.1002/ksa.12180.
12. Tokumoto Y, Nakagawa Y, Nakamura T, et al. Combined medial meniscus repair, centralization, and high tibial osteotomy are associated with improved clinical, radiological, and arthroscopic outcomes in patients with posterior root tears and varus alignment. *Arthroscopy*. Jul 16 2025. https://doi.org/10.1016/j.arthro.2025.07.003.
13. Park HJ, Chang MJ, Cho HJ, et al. Medial Meniscus Posterior root repair restores contact pressure and contact area to its native state Even after opening-wedge high tibial osteotomy: a cadaveric biomechanical study. *Arthroscopy*. Mar 2023;39(3):638–646. https://doi.org/10.1016/j.arthro.2022.09.009.
14. Gomi N, Muramoto H, Kataoka Y. Occurrence of patellofemoral joint osteoarthritis in long-term postoperative cases of open-wedge high tibial osteotomy: differences in symptoms based on patient-standing type evaluation with and without patellofemoral joint osteoarthritis. *Indian J Orthop*. Oct 2024;58(10):1411–1417. https://doi.org/10.1007/s43465-024-01250-z.
15. Goshima K, Sawaguchi T, Horii T, Shigemoto K, Iwai S, Hatsuchi Y. Patellofemoral osteoarthritis progression after open-wedge high tibial osteotomy does not affect the clinical outcomes or survivorship at minimum 7 years' Follow-Up. *Arthroscopy*. Jan 2024;40(1):93–102. https://doi.org/10.1016/j.arthro.2023.05.007.
16. Kondo E, Yasuda K, Yabuuchi K, et al. Inverted V-Shaped high tibial osteotomy for medial osteoarthritic knees with severe varus deformity. *Arthrosc Tech*. Oct 2018;7(10):e999–e1012. https://doi.org/10.1016/j.eats.2018.06.005.
17. Ollivier M, Claes S, Mabrouk A, et al. Surgical strategy and complication management of osteotomy around the painful degenerative varus knee: ESSKA formal consensus part II. *Knee Surg Sports Traumatol Arthrosc*. Aug 2024;32(8):2194–2205. https://doi.org/10.1002/ksa.12273.
18. Nakamura R, Amemiya M, Kawashima F, Okano A. Ankle-angle-adjusting fibular osteotomy in closed wedge high tibial osteotomy. *Arthrosc Tech*. Dec 2022;11(12):e2169–e2175. https://doi.org/10.1016/j.eats.2022.08.018.
19. Okazaki Y, Furumatsu T, Kodama Y, Kamatsuki Y, Masuda S, Ozaki T. Description of a surgical technique of medial meniscus root repair: a fixation technique with two simple stiches under an expected initial tension. *Eur J Orthop Surg Traumatol*. Apr 2019;29(3):705–709. https://doi.org/10.1007/s00590-018-2347-z.
20. Ueda D, Yasuda K, Kaibara T, et al. High rate of radiographic union at the fibular osteotomy site with No complications after an acute oblique osteotomy and ligation procedure to shorten the fibula in high tibial osteotomy. *Orthop J Sports Med*. Aug 2022;10(8), 23259671221117480. https://doi.org/10.1177/23259671221117480.
21. Hayashi S, Tsukisaka K, Okuhara A, Tsuyuguchi Y, Goto K, Hashiguchi N. Inverted V-Shaped high tibial osteotomy decreases the posterior tibial slope more but shortens the tibia less than closed-wedge high tibial osteotomy. *Arthroscopy*. Jun 2022;38(6):1956–1965. https://doi.org/10.1016/j.arthro.2021.12.008.
22. Takahashi T, Handa M, Kurabayashi H, Takeshita K. Combined transtibial medial Meniscus posterior root pullout repair and medial open wedge high tibial osteotomy. *Arthrosc Tech*. Jul 2025;14(7), 103592. https://doi.org/10.1016/j.eats.2025.103592.
23. Takigami J, Hashimoto Y, Tomihara T, Taniuchi M, Takahashi D, Katsuda H. Combined procedure of arthroscopic pullout medial meniscal root repair from lateral tibia and open-wedge distal tibial tubercle osteotomy. *Arthrosc Tech*. Sep 2024;13(9), 103031. https://doi.org/10.1016/j.eats.2024.103031.
24. Yanagisawa S, Kimura M, Hagiwara K, Ogoshi A, Omodaka T, Omae H. Evaluation of the bone tunnel position and state of healing on second-look arthroscopy after pullout repair of medial meniscus posterior root tear during open-wedge high tibial osteotomy. *Knee*. Jun 2023;42:220–226. https://doi.org/10.1016/j.knee.2023.03.016.
25. Vosoughi F, Vahedi P, Nakhjiri MT, et al. High tibial osteotomy and concurrent medial meniscus root repair provides improved objective outcomes compared to high tibial osteotomy alone for knee osteoarthritis: a systematic review. *Knee Surg Sports Traumatol Arthrosc*. Sep 2025;33(9):3361–3374. https://doi.org/10.1002/ksa.12796.
26. Sasaki E, Maeda S, Tsushima T, et al. Mid-term patient-reported outcomes are inferior in opening-wedge high tibial osteotomy patients with untreated medial meniscus posterior root tear. *J Exp Orthop*. Oct 2024;11(4), e70064. https://doi.org/10.1002/jeo2.70064.