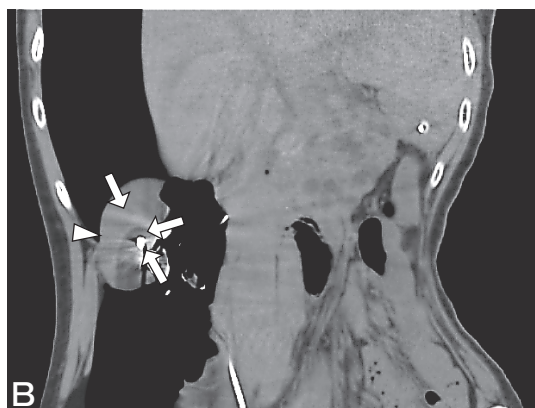


Erratum

In the article by Sekito *et al.* entitled “Combined Laparoscopic and CT Monitoring of the Ice-Ball Margin during Cryoablation for Renal Cell Carcinoma Associated with von Hippel-Lindau Disease: First Case”, which appeared in the October 2020 issue, Vol.74, No.5, pp443-448, Figure 1B should be corrected as below.

Error:



Correction:

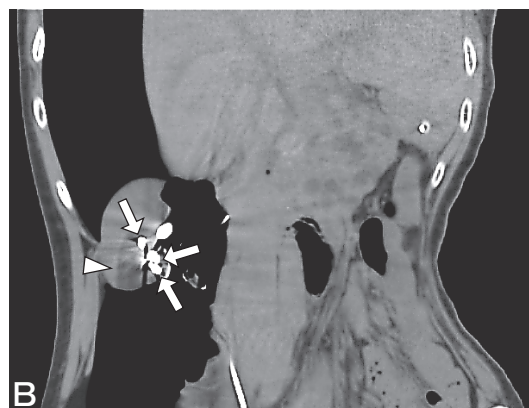


Fig. 1B, Plain CT at the end of the second freeze cycle demonstrated three cryoprobes (*arrows*) positioned within the renal mass. The ice-ball was detected as a well-demarcated region of hypodensity in the surrounding tissue (*arrowhead*).