



Case report

Extracorporeal membrane oxygenation in *Stenotrophomonas maltophilia* pneumonia during acute myeloid leukemia: A case reportKenki Saito^{a,*}, Toshiyuki Aokage^b, Takayuki Sato^a, Kohei Tsukahara^c, Fumiaki Tokioka^d, Takanao Otake^e, Hiromasa Irie^e, Yasunori Ueda^a^a Department of Hematology/Oncology, Kurashiki Central Hospital, Japan^b Department of Geriatric Emergency Medicine, Okayama University Graduate School of Medicine, Dentistry and Pharmaceutical Sciences, Okayama, Japan^c Department of Emergency, Critical Care and Disaster Medicine, Okayama University Hospital, Okayama, Japan^d Department of Respiratory Medicine, Kurashiki Central Hospital, Kurashiki, Japan^e Department of Anesthesiology, Kurashiki Central Hospital, Kurashiki, Japan

ARTICLE INFO

Keywords:

Stenotrophomonas maltophilia

Severe pneumonia

Acute panmyelosis with myelofibrosis

Acute myeloid leukemia

Extracorporeal membrane oxygenation

ABSTRACT

Stenotrophomonas maltophilia (*S. maltophilia*) is a Gram-negative, multidrug-resistant organism that both opportunistically infects the bloodstream and leads to pneumonia in immunosuppressed patients, including those with hematologic malignancies. In patients with severe respiratory failure, venovenous extracorporeal membrane oxygenation (VV ECMO) can stabilize the respiratory status. However, whether ECMO in patients with hematologic malignancies improves the clinical outcomes is still controversial because ECMO increases the risk of the exacerbation of sepsis and bleeding. We report a case of a 46-year-old man with *Stenotrophomonas maltophilia* hemorrhagic pneumonia acquired during consolidation chemotherapy for acute myeloid leukemia in whom VV ECMO lead to a good clinical outcome. The stabilization of his respiratory status achieved with VV ECMO allowed time for trimethoprim-sulfamethoxazole antibiotic therapy to improve the pneumonia. We suggest the background of patients, including comorbidities and general conditions, should be taken into account when considering the clinical indications of ECMO.

1. Introduction

Stenotrophomonas maltophilia (*S. maltophilia*) is a Gram-negative, obligate, rod-shaped, multidrug-resistant aerobe that has been isolated from aqueous-associated sources in both nosocomial and community settings [1,2]. Although it is of low virulence, it acts as an opportunistic pathogen, leading to severe sepsis and pneumonia by action of a protease-initiated insult of lung tissue leading to hemorrhage [4,5] in immunosuppressed patients, including those with hematologic malignancies [3]. Hemorrhagic pneumonia caused by *S. maltophilia* in hematologic malignancies usually has a fatal course [6].

Extracorporeal gas exchange is a technique that enables gas exchange by the extracorporeal circulation of blood through an artificial organ [7]. Venovenous extracorporeal membrane oxygenation (VV ECMO) is a mechanical-assisted therapy for the extracorporeal gas exchange in patients with severe respiratory failure, which oxygenates and removes carbon dioxide from the blood [8,9]. VV ECMO has been reported as successful in limited case studies for acute pneumonia with

hematologic malignancies, including in *S. maltophilia* hemorrhagic pneumonia associated with hematologic malignancies [10,11].

Here, we present a case of *S. maltophilia* hemorrhagic pneumonia in a 45-year-old man treated with VV ECMO during consolidation chemotherapy for acute myeloid leukemia. After VV ECMO therapy, he fully regained his functional status and was commenced on subsequent consolidation chemotherapy and allogeneic hematopoietic stem cell transplantation.

This study was approved by the Institutional Review Board of Kurashiki Central Hospital and was conducted according to the principles of the Declaration of Helsinki. In accordance with the ethical concerns of the Institutional Review Board of Kurashiki Central Hospital, patient confidentiality was protected by removing or masking patient identifiers, and informed consent was obtained from the patient for the publication of this case report and accompanying images.

* Corresponding author.

E-mail address: ks16149@kchnet.or.jp (K. Saito).<https://doi.org/10.1016/j.rmcr.2020.101224>

Received 30 July 2020; Received in revised form 10 September 2020; Accepted 10 September 2020

Available online 14 September 2020

2213-0071/© 2020 The Author(s).

Published by Elsevier Ltd.

This is an open access article under the CC BY-NC-ND license

<http://creativecommons.org/licenses/by-nc-nd/4.0/>.

2. Case presentation

A 45-year-old man was referred to and admitted to our hospital after visiting a local clinic with complaints of general malaise, fever and a 2-week history of purpura. Laboratory analysis revealed pancytopenia. On admission, laboratory data revealed leukopenia ($1.4 \times 10^9/L$), anemia (hemoglobin 4.5 g/dL), and thrombocytopenia (undetectable). Computed tomography (CT) showed a diffusely increased bone marrow concentration, but did not show liver or splenic enlargement. Bone marrow aspiration was unsuccessful, leading to bone marrow biopsy, which revealed acute panmyelosis with myelofibrosis, a rare subtype of acute myeloid leukemia. Induction therapy (idarubicin hydrochloride 12 mg/m² for three days and cytosine arabinoside 100 mg/m²/day for seven days) was started on day 8. His clinical course is shown in Fig. 1. Cefazopran treatment for febrile neutropenia was started on day 2. Left cheek cellulitis appeared on day 20, which failed to respond to cefazopran treatment, and was thereafter switched to meropenem/vancomycin treatment on day 29. After confirming blood cell recovery and improved cellulitis, antibiotic therapy was switched to levofloxacin on day 38. Bone marrow aspiration failed again at the end of the induction therapy. Peripheral blood cell count was within normal limits, and Wilm's tumor 1 mRNA count decreased from 37,000 copies/μg mRNA (reference level <50 copies/μg RNA) on day 3–150 copies/μg mRNA on day 38. We determined that he had achieved hematological complete remission, and consolidation therapy (cytosine arabinoside 2000 mg/m² × 2/day for five days) was started. Because of febrile neutropenia on day 49, we switched levofloxacin to cefazopran. Despite antibiotic therapy, he showed sustained hyperthermia again on day 54. A blood culture test was performed, and the indwelling central venous catheter was removed. A chest radiograph on day 56 showed pneumonia in the entire right lung field. We switched treatment from cefazopran to meropenem and amikacin for possible *Pseudomonas aeruginosa* pneumonia, which was ineffective. He was transferred to the intensive care unit (ICU) on the same day and underwent intubation on day 57. Both blood and sputum cultures revealed *S. maltophilia*, and trimethoprim-sulfamethoxazole (SMX-TMP) was administered, for which

S. maltophilia was susceptible to, in addition to levofloxacin, ceftazidime, and minocycline. Hematic tracheal aspirates were reported on around day 60.

Intravenous granulocyte-colony stimulating factor in combination with SMX-TMP was administered for febrile neutropenia. As the neutropenia resolved, his ventilator condition gradually deteriorated further from day 63. Airway pressure-release ventilation plus intermittent prone positioning was initiated on day 66, which failed to improve his respiratory failure. PaO₂/FiO₂ was 69.5 with an FiO₂ of 0.85 (PaCO₂ 40 mmHg) and a respiratory rate of 20; a positive end-expiratory pressure (PEEP) of 14; and a peak inspiratory pressure (PIP) of 27 cmH₂O. Chest CT showed massive consolidation in both lung fields and opacities around them. During this period, the use of catecholamines was gradually reduced. According to acute respiratory distress syndrome (ARDS) criteria [12], the patient met each criterion and was considered to have severe ARDS. Bronchoalveolar lavage showed cell counts of 600/μL (neutrophils, 59%; lymphocytes, 31%; atypical lymphocytes, 2%; and macrophages, 8%). In addition, both blood and sputum cultures yielded negative, which suggested antibiotic therapy with SMX-TMP was successful. Due to high ventilator pressures and high oxygen demand, VV ECMO was considered, and after careful evaluation was initiated (day 68, day 12 of invasive ventilation). We obtained 4.2 L/min of blood flow with 5 L/min of sweep gas, and the ventilator setting was lowered to an FiO₂ of 0.4, a PIP of 20 cmH₂O, and a PEEP of 10 cmH₂O for resting the lungs. After lowering the ventilator pressure, the whole right lung and part of the left lung were observed as collapsed, and ventilation and oxygenation became completely VV ECMO-dependent. Tracheotomy was performed on day 71, and he was partially awakened. His lungs gradually opened up while regaining spontaneous breathing and active mobilization of bronchial secretions. On day 79, the patient was weaned off VV ECMO and was subsequently treated with mechanical ventilation support. Bilateral pulmonary infiltration improved after antibiotic therapy and ventilation therapy including VV ECMO (Fig. 2).

Biphasic positive airway pressure was weaned on day 88, and oxygen supplementation was discontinued on day 131. He was discharged from the hospital on day 145, with a markedly improved pneumonia on chest

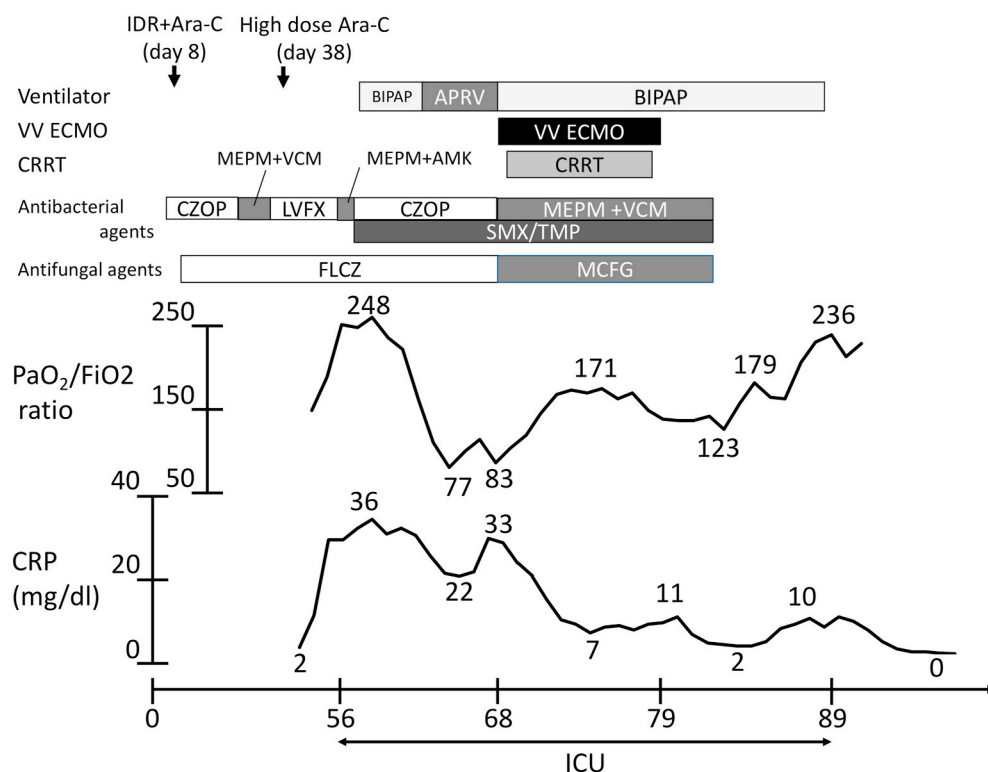


Fig. 1. The clinical course. C-reactive protein and PaO₂/FiO₂ ratio were improved by both antibiotic therapy and ECMO therapy. Abbreviations: IDR, idarubicin hydrochloride; Ara-C, cytosine arabinoside; CAZ, ceftazidime; CRP, C-reactive protein; CZOP, cefazopran; MEPM, meropenem; VCM, vancomycin; LVFX, levofloxacin; AMK, amikacin; SMX/TMP, sulfamethoxazole-trimethoprim; FLCZ, fluconazole; MCFG, micafungin; APRV, airway pressure-release ventilation; VV ECMO, venovenous extracorporeal membrane oxygenation; BIPAP, biphasic positive airway pressure; CRRT, continuous renal replacement therapy.

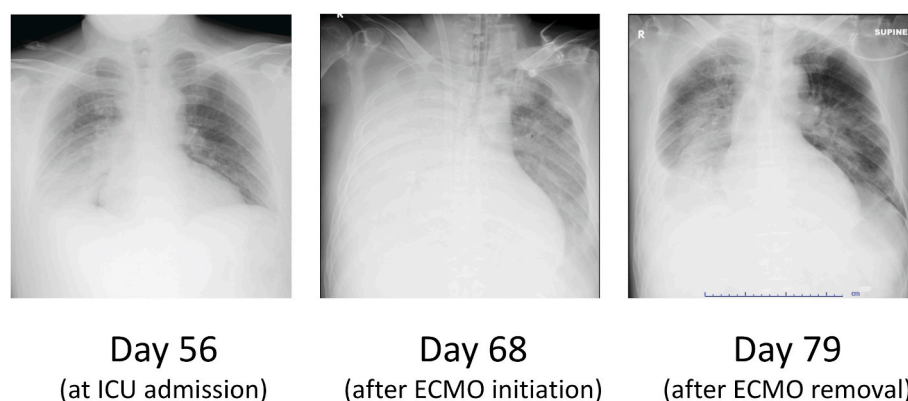


Fig. 2. Bilateral pulmonary infiltration improved after antibiotic therapy and ventilation therapy including venovenous extracorporeal membrane oxygenation (Chest radiographs on days 56, 68, and 79). Abbreviations: VV ECMO, venovenous extracorporeal membrane oxygenation; ICU; intensive care unit.

CT. Additional consolidation chemotherapy was postponed until he recovered his physical strength. After he fully regained his functional status, he received subsequent consolidation chemotherapy and allogeneic hematopoietic stem cell transplantation. At the time of writing, he maintains in complete remission.

3. Discussion

The isolation rate of *S. maltophilia* is increasing due to recent developments in respiratory management and medical devices because *S. maltophilia* has the ability to spread and colonize along the respiratory tract and medical devices [1,2]. Host risk factors, including hematologic malignancies, an immune compromised state, the use of broad-spectrum antibiotics, and combination therapy with three or more antibiotics, have also been investigated [13]. In our case, we hypothesized that hematological malignancies and therapy with multiple antibiotics, including cefazopran, meropenem, levofloxacin, and vancomycin, may have resulted in *S. maltophilia* pneumonia. StmPr1 protease produced by *S. maltophilia* has degradative and cytotoxic actions, which leads to lung tissue damage and inflammation. [4,5]. Hemorrhagic pneumonia caused by *S. maltophilia* progresses rapidly and can be fatal [6].

SMX-TMP is the antibacterial treatment of choice against *S. maltophilia*. However, its efficacy remains controversial for patients with hemorrhagic pneumonia because of its rapidly progressive course. In earlier case reports, treatments for *S. maltophilia* hemorrhagic pneumonia using polymyxin [14] and fluoroquinolone [15] in combination with SMX-TMP were successful. However, these studies are limited by their small patient populations, leaving the efficacy of these regimens unclear.

The mortality of acute pneumonia for patients with hematological malignancies is high compared to patients without [16]. The number of patients requiring ICU treatment over the last decade has increased with the development of chemotherapy for hematological malignancies and its resulting expansion of indications for chemotherapy [17,18]. In contrast, the mortality of patients who require mechanical ventilation for pneumonia associated with the treatment of hematological malignancies is still high at approximately 70% [18]. Patient factors that influence treatment resistance include neutropenia, fungal infections, sepsis, and the treatment responsiveness to underlying hematological malignancies [19].

The ICU treatment of hemorrhagic pneumonia due to *S. maltophilia* associated with hematological malignancies is challenging. Therefore, strict patient selection is required when considering whether ECMO is clinically appropriate in each patient. The CESAR randomized control trial has demonstrated the effectiveness of ECMO for ARDS [20]. In contrast, the effectiveness of ECMO for hematologic malignancies is yet to be clarified. In addition, the 6-month survival of patients on ECMO due to respiratory failure associated with hematological malignancies

was as low as 25% [21].

Some intensive care physicians are hesitant with administering ECMO because of the risk leading to the exacerbation of infection, sepsis, and ICU-acquired weakness [21,22]. While this debate continues, our stance is to consider ECMO for patients with acute reversible respiratory failure, even those with hematologic malignancies and of immunocompromised status, if they meet the following criteria: (1) Infectious pneumonia with an available evidence-based antibiotic treatment, (2) A potentially curable hematological malignancy, (3) No diagnosis of chronic respiratory disease and active uncontrollable bleeding, (4) The patient is less 65 years old, (5) No recent history of a bone marrow transplant.

Pneumonia with an available evidence-based antibiotic treatment and a potentially curable hematological malignancy are essential because ECMO is primarily for the stabilization of respiratory status. In contrast to hematologic malignancies, ARDS associated with bone marrow transplantation is a contraindication of ECMO. We have experienced many patients who experienced ARDS following bone marrow transplantation and developed pulmonary fibrosis, and patients who have recently received bone marrow transplantation are defined as a contraindication to ECMO in our medical department, which is consistent with data from the ELSO registry [23]. Patients aged 65 and over with chronic respiratory failure are contraindications for ECMO use in the earlier literature [24,25]. Age is an important prognostic factor in hematological malignancies as a result of the substantial physiological demands of chemotherapy in patients of advanced age. Overall survival in elderly patients aged 65 or older with acute myeloid leukemia is less than 10%, which is lower than that of younger patients due to the differences in both tumor and patient characteristics [26,27]. As ECMO is used for the primary purpose of life support, ECMO should not be used in elderly patients with a diagnosis of acute myeloid leukemia and a poor prognosis for long-term survival. In our case, inclusion factors of the patient being in complete remission, diagnosis of *S. maltophilia* infection, and in hemostasis were met, leading to the commencement of VV ECMO. Thereafter, we lowered the ventilator settings to prevent the progression of ventilator-induced lung injury. In addition, awake management and mobilization prevented ICU-acquired weakness, and maintenance of spontaneous breathing assisted clearance of bronchial secretions and improvement of the pneumonia.

Hemorrhagic pneumonia caused by *S. maltophilia* can be potentially resolved with SMX-TMP. However, death due to respiratory failure may occur because of its rapid progression, and VV ECMO is one method of stabilizing the patient until recovery is achieved. Awake management and mobilization prevents ICU-acquired weakness, and maintenance of spontaneous breathing assists clearance of bronchial secretions and improvement of pneumonia. Note that VV ECMO use should be limited to the patients with the criteria described above. VV ECMO is not clinically appropriate in all patients with hematological malignancies who

experience severe respiratory failure.

Declarations of interest

The authors have no financial or non-financial competing interests related to this case report.

Funding

There is no funding associated with this case report.

References

- [1] J.S. Brooke, *Stenotrophomonas maltophilia*: an emerging global opportunistic pathogen, *Clin. Microbiol. Rev.* 25 (1) (2012) 2–41, <https://doi.org/10.1128/CMR.00019-11>.
- [2] W.J. Looney, M. Narita, K. Mühlemann, *Stenotrophomonas maltophilia*: an emerging opportunist human pathogen, *Lancet Infect. Dis.* 9 (5) (2009) 312–323, [https://doi.org/10.1016/S1473-3099\(09\)70083-0](https://doi.org/10.1016/S1473-3099(09)70083-0).
- [3] S.Y. Cho, D.G. Lee, S.M. Choi, et al., *Stenotrophomonas maltophilia* bloodstream infection in patients with hematologic malignancies: a retrospective study and in vitro activities of antimicrobial combinations, *BMC Infect. Dis.* 15 (2015) 69, <https://doi.org/10.1186/s12879-015-0801-7>. Published 2015 Feb 18.
- [4] S. Windhorst, E. Frank, D.N. Georgieva, et al., The major extracellular protease of the nosocomial pathogen *Stenotrophomonas maltophilia*: characterization of the protein and molecular cloning of the gene, *J. Biol. Chem.* 277 (13) (2002) 11042–11049, <https://doi.org/10.1074/jbc.M109525200>.
- [5] A.L. DuMont, N.P. Cianciotto, *Stenotrophomonas maltophilia* serine protease StmPr1 induces matrilysin, anoinis, and protease-activated receptor 2 activation in human lung epithelial cells, *infect. Immun.* 85 (12) (2017), <https://doi.org/10.1128/IAI.00544-17>. Published 2017 Nov 17.
- [6] M. Mori, H. Tsunemine, K. Imada, K. Ito, T. Kodaka, T. Takahashi, Life-threatening hemorrhagic pneumonia caused by *Stenotrophomonas maltophilia* in the treatment of hematologic diseases, *Ann. Hematol.* 93 (6) (2014) 901–911, <https://doi.org/10.1007/s00277-014-2028-x>.
- [7] A. Pesenti, A. Zanella, N. Patroniti, Extracorporeal gas exchange, *Curr. Opin. Crit. Care* 15 (1) (2009) 52–58, <https://doi.org/10.1097/MCC.0b013e3283220e1f>.
- [8] D. Brodie, M. Bacchetta, Extracorporeal membrane oxygenation for ARDS in adults, *N. Engl. J. Med.* 365 (20) (2011) 1905–1914, <https://doi.org/10.1056/NEJMct1103720>.
- [9] T. Aokage, K. Palmér, S. Ichiba, S. Takeda, Extracorporeal membrane oxygenation for acute respiratory distress syndrome, *J. Intensive Care* 3 (2015) 17, <https://doi.org/10.1186/s40560-015-0082-7>. Published 2015 Jun 17.
- [10] P. Wohlfarth, R. Ullrich, T. Staedinger, et al., Extracorporeal membrane oxygenation in adult patients with hematologic malignancies and severe acute respiratory failure, *Crit. Care* 18 (1) (2014) R20, <https://doi.org/10.1186/cc13701>. Published 2014 Jan 20.
- [11] N.A. Huprikar, M.R. Peterson, J.D. DellaVolpe, et al., Salvage extracorporeal membrane oxygenation in induction-associated acute respiratory distress syndrome in acute leukemia patients: a case series, *Int. J. Artif. Organs* 42 (1) (2019) 49–54, <https://doi.org/10.1177/0391398818799160>.
- [12] ARDS Definition Task Force, V.M. Ranieri, G.D. Rubenfeld, et al., Acute respiratory distress syndrome: the Berlin Definition, *J. Am. Med. Assoc.* 307 (23) (2012) 2526–2533, <https://doi.org/10.1001/jama.2012.5669>.
- [13] S.H. Kim, S.Y. Cho, C.I. Kang, et al., Clinical predictors of *Stenotrophomonas maltophilia* bacteremia in adult patients with hematologic malignancy, *Ann. Hematol.* 97 (2) (2018) 343–350, <https://doi.org/10.1007/s00277-017-3178-4>.
- [14] S.C. Penagos, N. Giraldo, C. Vallejo, O. McEwen, A. Hidron, First report of survival in two patients with hematologic malignancy and *Stenotrophomonas maltophilia* hemorrhagic pneumonia treated with trimethoprim-sulfamethoxazole-based combination antibiotic therapy, *J. Infect. Chemother.* 26 (4) (2020) 397–399, <https://doi.org/10.1016/j.jiac.2019.12.003>.
- [15] N. Guzoglu, F.N. Demirkol, D. Aliefendioğlu, Haemorrhagic pneumonia caused by *Stenotrophomonas maltophilia* in two newborns, *J. Infect. Dev. Ctries* 9 (5) (2015) 533–535, <https://doi.org/10.3855/jidc.5463>. Published 2015 May 18.
- [16] E. Azoulay, D. Mokart, F. Pène, et al., Outcomes of critically ill patients with hematologic malignancies: prospective multicenter data from France and Belgium—a groupe de recherche respiratoire en réanimation onco-hématologique study, *J. Clin. Oncol.* 31 (22) (2013) 2810–2818, <https://doi.org/10.1200/JCO.2012.47.2365>.
- [17] E. Azoulay, F. Pène, M. Darmon, et al., Managing critically ill hematology patients: time to think differently, *Blood Rev.* 29 (6) (2015) 359–367, <https://doi.org/10.1016/j.blre.2015.04.002>.
- [18] H.M. Al-Dorzi, H. Al Orainni, F. Al Eid, et al., Characteristics and predictors of mortality of patients with hematologic malignancies requiring invasive mechanical ventilation, *Ann. Thorac. Med.* 12 (4) (2017) 259–265, <https://doi.org/10.4103/atm.ATM.21.17>.
- [19] D. Lagier, L. Platon, L. Chow-Chine, et al., Severity of Acute Respiratory Distress Syndrome in haematology patients: long-term impact and early predictive factors, *Anaesthesia* 71 (9) (2016) 1081–1090, <https://doi.org/10.1111/anae.13542>.
- [20] G.J. Peek, M. Mugford, R. Tiruvoipati, et al., Efficacy and economic assessment of conventional ventilatory support versus extracorporeal membrane oxygenation for severe adult respiratory failure (CESAR): a multicentre randomised controlled trial [published correction appears in *Lancet*. 2009 Oct 17;374(9698):1330], *Lancet* 374 (9698) (2009) 1351–1363, [https://doi.org/10.1016/S0140-6736\(09\)61069-2](https://doi.org/10.1016/S0140-6736(09)61069-2).
- [21] M. Schmidt, D. Brodie, A. Combes, Patients with hematologic malignancies have many reasons to die during extracorporeal membrane oxygenation, *Crit. Care* 18 (5) (2014) 522, <https://doi.org/10.1186/s13054-014-0522-0>. Published 2014 Sep. 15.
- [22] ELSO Guidelines for Cardiopulmonary Extracorporeal Life Support, Extracorporeal Life Support Organization, Ann Arbor, MI, USA, August 2017. Version 1.4, <https://www.else.org/Portals/0/ELSO%20Guidelines%20For%20Adult%20Respiratory%20Failure%201.4.pdf>. (Accessed 3 September 2020).
- [23] M. Gupta, T.P. Shanley, F.W. Moler, Extracorporeal life support for severe respiratory failure in children with immune compromised conditions, *Pediatr. Crit. Care Med.* 9 (4) (2008) 380–385, <https://doi.org/10.1097/PCC.0b013e318172d54d>.
- [24] M. Schmidt, M. Bailey, J. Sheldrake, et al., Predicting survival after extracorporeal membrane oxygenation for severe acute respiratory failure. The Respiratory Extracorporeal Membrane Oxygenation Survival Prediction (RESP) score, *Am. J. Respir. Crit. Care Med.* 189 (11) (2014) 1374–1382, <https://doi.org/10.1164/rccm.201311-2023OC>.
- [25] P. Mendiratta, X. Tang, R.T. Collins 2nd, P. Rycus, T.V. Brogan, P. Prodhon, Extracorporeal membrane oxygenation for respiratory failure in the elderly: a review of the Extracorporeal Life Support Organization registry, *Am. Soc. Artif. Intern. Organs J.* 60 (4) (2014) 385–390, <https://doi.org/10.1097/MAT.0000000000000090>.
- [26] National Cancer Institute, SEER cancer statistics review, 1975–2009 (vintage 2009 populations). https://seer.cancer.gov/archive/csr/1975_2009_pops09/. (Accessed 3 September 2020).
- [27] H.D. Klepin, A.V. Rao, T.S. Pardee, Acute myeloid leukemia and myelodysplastic syndromes in older adults, *J. Clin. Oncol.* 32 (24) (2014) 2541–2552, <https://doi.org/10.1200/JCO.2014.55.1564>.