

Case Report

Hepatic Arterial Infusion Chemotherapy Prior to Standard Systemic Chemotherapy in Patients with Highly Advanced Unresectable Liver Metastases from Colorectal Cancer: A Report of Three Patients

Toshihiro Iguchi^{a*}, Hitoshi Idani^b, Shinya Asami^b, Hisashi Endo^c,
Yoshitaka Inaba^d, Yasuaki Arai^e, and Susumu Kanazawa^f

Departments of ^aRadiology, ^bSurgery, and ^cMedical Oncology, Fukuyama City Hospital, Fukuyama, Hiroshima 721-8511, Japan,

^dDepartment of Diagnostic and Interventional Radiology, Aichi Cancer Center Hospital, Nagoya 464-8681, Japan,

^eDepartment of Diagnostic Radiology, National Cancer Center Hospital, Tokyo 104-0045, Japan, and ^fDepartment of Radiology, Okayama University Graduate School of Medicine, Dentistry and Pharmaceutical Sciences, Okayama 700-8558, Japan

We administered hepatic arterial infusion chemotherapy (HAIC) prior to FOLFOX to three patients with unresectable liver metastases from colorectal cancer. The patients' disease state was found to be highly advanced based on both computed tomography findings and liver function tests. The treatment strategy included an initial administration of HAIC to control liver metastases and improve liver function in order to facilitate the subsequent safe administration of FOLFOX without drug loss. As the HAIC regimen, 1,000 mg/m² of 5-FU was administered weekly by continuous 5-h infusion after performing laboratory investigations through an implanted port-catheter system. After 3 HAIC cycles administered over 3 consecutive weeks, the mean alkaline phosphatase levels decreased from 969.3 IU/l to 422 IU/l due to shrinkage of the liver metastases. Thereafter, FOLFOX without drug loss could be safely initiated for all patients. Two patients succumbed 488 and 333 days after HAIC was initiated; the third patient is still alive and has been followed-up for 1215 days. The combined use of HAIC and standard systemic chemotherapy could be a feasible and efficacious treatment in highly advanced cases of liver dysfunction.

Key words: colorectal cancer, hepatic arterial infusion chemotherapy, liver metastasis, port-catheter system

Systemic chemotherapy is usually the preferred treatment for unresectable liver metastases from colorectal cancer [1]. With recent advances in new drugs and the standardization of chemotherapy regimens for colorectal cancer, patient survival has been prolonged. Currently, FOLFOX (5-fluorouracil

(5-FU)/leucovorin with oxaliplatin) and FOLFIRI (5-FU/leucovorin with irinotecan) are used as standard chemotherapy regimens [1, 2], and the median survival with these regimens is reported to be 20.6–21.5 months [2]. The addition of bevacizumab to these regimens further prolongs the survival [3]. However, in patients with highly advanced unresectable liver metastases, it is vital but very difficult to select the initial treatment regimen because it is often impossible to perform further treatment if the initial treatment

Received April 21, 2010; accepted August 26, 2010.

*Corresponding author. Phone: +81-84-941-5151; Fax: +81-84-941-5159

E-mail: iguchi@ba2.so-net.ne.jp (T. Iguchi)

fails. Fakih MG has reported that three patients with metastatic colon cancer and severe liver dysfunction were treated by FOLFOX [4]. After the initial improvement in disease status, disease progression was noted in 2 patients at 4 and 7 months from the inception of therapy, while treatment was ongoing in the third patient at 5 months.

Repeated hepatic arterial infusion chemotherapy (HAIC) through an implanted port-catheter system is an effective therapy for unresectable liver metastases from colorectal cancer [5–7]. Compared to systemic chemotherapy, HAIC increases the possibility of tumor response and might improve liver function by shrinking liver metastases [7–10]; however, a comparison was not made between HAIC with FOLFOX and HAIC with FOLFIRI in those reports. The administration of high doses of 5-FU, which is used as an HAIC regimen in Japan, is particularly associated with a good tumor response and patient-survival rates, and has fewer and less severe adverse events [5, 11].

We administered HAIC prior to FOLFOX to 3 patients with highly advanced unresectable liver metastases from colorectal cancer; further treatment in the event of failure of the initial treatment was considered impossible in these patients. The treatment strategy involved an initial administration of HAIC to control liver metastases and improve liver function in order to facilitate the subsequent safe administration of FOLFOX without drug loss. This strategy was formulated on the basis of the high tumor-response rate and the fewer and less severe adverse effects associated with HAIC.

Case Report

This report was approved by our institutional review board, and written informed consent was

obtained from each patient.

Between November 2006 and April 2007, 69 patients were admitted to undergo initial therapy for colorectal cancer at our institution. Of those patients, three consecutive patients (2 men and 1 woman; mean age, 56.0 years) had highly advanced synchronous liver metastases. In all three patients, liver metastases were judged to be unresectable due to liver dysfunction and multiple metastases in both the right and left lobes of the liver. The primary cancer sites were the descending colon ($n=1$), sigmoid colon ($n=1$), and rectum ($n=1$). The patient characteristics are shown in Table 1.

Our treatment strategy was as follows. First, surgical resection of primary colorectal cancer was performed. Next, we repeatedly administered HAIC through an implanted port-catheter system as the initial treatment for liver metastases, considering our patients' advanced state of disease, as indicated by both the computed tomography (CT) findings (Aquilion 64; Toshiba, Tokyo, Japan) and the results of liver function tests. As the HAIC regimen, 1,000mg/m² of 5-FU was administered weekly by continuous 5-h infusion after performing laboratory investigations [5]. The levels of alkaline phosphatase (ALP) were more than 2.5 times the upper limit of normal (ULN; 875IU/l) due to the liver metastases; thus, this value was used as an index for HAIC continuation. HAIC was administered weekly to control the liver metastases until the ALP levels were within 1.5 times the ULN (525IU/l). Thereafter, FOLFOX without drug loss was started.

The patients underwent curative surgical resection of primary colorectal cancer and lymph node metastases. Metastases in N1 lymph nodes were observed in 2 patients; 1 patient showed N2 lymph node metastases. Extrahepatic metastases in the lung, bone, brain,

Table 1 Patients Characteristics

Case	Age (y.o)/Sex	Primary Site	Liver Function before starting HAIC/after HAIC					Tumor Marker before starting HAIC/after HAIC		Liver Metastases Volume (%) [§] before starting HAIC/after 3 times HAIC	Follow-up Period(d)	Alive/Dead
			ALP (IU/l)	LDH (IU/l)	AST (IU/l)	ALT (IU/l)	T-BIL (mg/dl)	CEA	CA19-9			
1	58/F	D-colon	971/349	710/303	37/23	27/8	0.4/0.5	3,258.9/389.3	11,184/1,302	42.8/33.9	333	Dead
2	55/M	S-colon	927/401	1,045/312	59/27	54/27	0.4/0.4	65.4/42.1	70/56	53.6/45.2	1,215	Alive
3	55/M	rectum	1,010/516	714/303	32/22	26/22	0.7/0.6	92.8/23.6	13/1.4	31.9/22.3	488	Dead

D-colon, descending colon; S-colon, sigmoid colon; HAIC, hepatic arterial infusion chemotherapy; ALP, alkaline phosphatase; LDH, lactate dehydrogenase; AST, aspartate aminotransferase; ALT, alanine aminotransferase; T-BIL, total bilirubin. [§]Liver metastases volume (%) was estimated using the following formula: liver metastases volume (ml)/[normal liver parenchymal volume (ml) + liver metastases volume (ml)] × 100.

and peritoneum were not observed in the patients.

Radiological placement of the port-catheter system was performed at 14, 20, and 21 days after surgery (Fig. 1). All placement procedures were performed in an angiography suite under local anesthesia. Prior to catheter placement, the patients underwent angiography and arterial embolization to allow arterial mapping and prevent extrahepatic influx of 5-FU; these procedures were performed using a 4-French angiographic catheter (Clinical Supply, Gifu, Japan) that was inserted from the left femoral artery. The extrahepatic arteries that branched from the hepatic artery such as the right gastric artery and the posterior superior pancreaticoduodenal artery were embolized with microcoils (Trufill; Cordis, Miami Lakes, FL, USA) through a 2.1-French microcatheter (Sniper 2; Clinical Supply) inserted coaxially. Next, a 4-French angiographic catheter was inserted from the right femoral artery and advanced to the common hepatic artery via the celiac artery. An indwelling catheter (W spiral catheter; PIOLAX, Yokohama, Japan) with a side hole was then inserted using the catheter-exchange method. The catheter tip was inserted into the gastroduodenal artery such that the side hole was placed in the common hepatic artery. The gastroduodenal artery around the tip of the indwelling catheter was embolized using microcoils

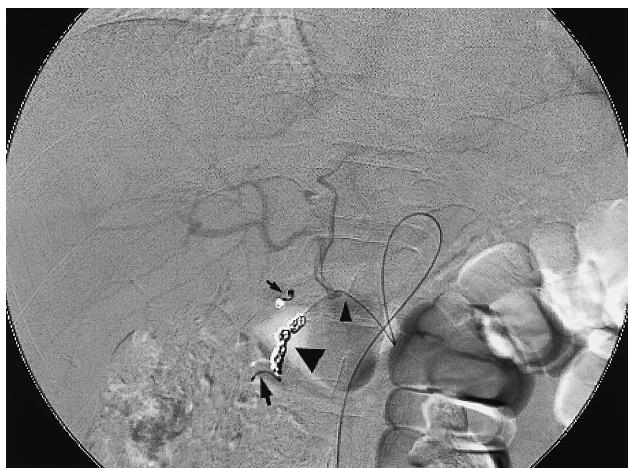

Fig. 1 Arteriogram via port shows that all hepatic arteries are well-visualized. The catheter tip is inserted into the gastroduodenal artery (arrow). The side hole is placed into the common hepatic artery (small arrowhead). To prevent an extrahepatic influx of anti-cancer agents, the gastroduodenal artery (arrowhead) and right gastric artery (small arrow) are embolized with microcoils.

through a microcatheter inserted coaxially via the angiographic catheter inserted from the left femoral artery. Finally, the proximal end of the indwelling catheter was connected to a port implanted in the subcutaneous pocket created in the right thigh. No complications such as hematoma, infections, and hepatic artery injuries and occlusions occurred during or after the procedure.

On the following day, digital subtraction angiography and CT were performed during injection of a contrast medium through the implanted port-catheter system to confirm that the catheter was not dislodged and to ensure that the entire liver was perfused adequately [12]. Thereafter, HAIC was administered through the port-catheter system. After the administration of 5-FU, this system was flushed and filled with 2ml heparin solution (1,000 IU/ml). The results of the liver function tests of the patients before starting HAIC were as follows: mean ALP, 969.3 IU/l; mean lactate dehydrogenase (LDH), 823 IU/l; mean aspartate aminotransferase (AST), 42.7 IU/l; mean alanine aminotransferase (ALT), 35.7 IU/l; and mean total bilirubin (T-BIL), 0.5 mg/dl (Table 1). In all patients, the percentage of liver involvement with metastases exceeded 30% (mean, 42.8%), as determined using contrast-enhanced CT and a workstation (Ziostation; Ziosoft, Tokyo, Japan).

After starting HAIC, no adverse events were observed in any of the patients. The ALP levels and other liver function parameters decreased to <1.5 times the ULN after 3 HAIC cycles administered over 3 consecutive weeks (Table 1). The results of the liver function tests performed after HAIC administration were as follows: mean ALP, 422 IU/l; mean LDH, 306 IU/l; mean AST, 24 IU/l; mean ALT 19 IU/l; and mean T-BIL, 0.5 mg/dl. Though three patients had stable disease, according to RECIST criteria [13], on contrast-enhanced CT, the percentage of liver involvement with metastases decreased (mean, 33.8%) (Fig. 2). Thereafter, FOLFOX without drug loss could be safely initiated for all patients, and the chemotherapy regimen was changed to FOLFIRI after FOLFOX had failed.

FOLFOX and FOLFIRI were administered a total of 12 times in case 1 and 11 times in case 3, respectively. The systemic chemotherapy failed to produce a positive response in these patients and could not be continued. Their performance status worsened be-

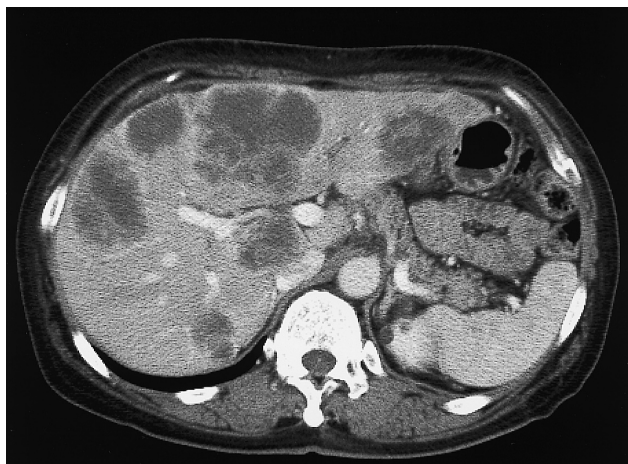


Fig. 2A A 58-year-old woman with multiple liver metastases from cancer of the descending colon. Contrast-enhanced CT image obtained before the initiation of HAIC showing multiple unresectable liver metastases in both the right and left lobes of the liver.

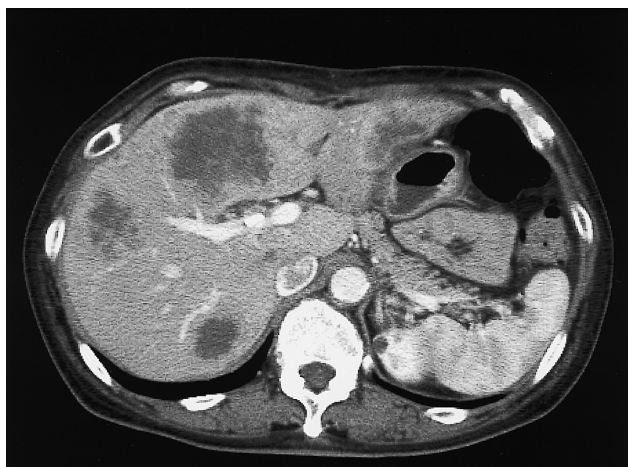

Fig. 2B Contrast-enhanced CT image obtained after 3 HAIC cycles showing smaller liver metastases. The percentage of liver involvement with metastases improved from 42.8% to 33.9%.

cause their liver metastases progressed; HAIC was therefore readministered to both patients (16 times for one patient and 6 times for the other). The case 1 patient succumbed to the disease 488 days after HAIC was initiated; case 3 succumbed after 333 days.

In case 2, FOLFOX and FOLFIRI were administered a total of 24 times. Afterward, another systemic chemotherapy was administered because he failed to respond to these treatment regimens. At

present, he is still alive and has been followed-up for 1215 days.

Discussion

HAIC for unresectable liver metastases from colorectal cancer was evaluated in 3 different meta-analyses [8–10]; compared with systemic chemotherapy, HAIC was associated with a superior response rate, but it did not improve patient survival. Conversely, in Japan, it has been reported that the response rate of patients to HAIC is 78%, and the median survival time is 25.8 months after intermittent HAIC with high doses of 5-FU [5]. It seems that these positive results were an outcome of a number of contributing factors, including appropriate techniques for port-catheter system placement and evaluation of drug distribution using CT during arteriography [5, 12]. Additionally, this regimen has the advantage of being considerably cheaper than the current standard systemic chemotherapy and usually has fewer and less severe adverse events than systemic chemotherapy [5].

On the basis of its superior tumor response and the possibility of improved liver function, HAIC was administered prior to systemic chemotherapy in order to treat advanced unresectable liver metastases. HAIC was useful because it improved liver function in our patients by shrinking liver metastases and enabling the safe administration of standard systemic chemotherapy without drug loss. A positive relationship between dose intensity and response rate has been documented in the treatment of advanced colon cancers [14]; therefore, a lower prospective tumor response and a shorter prospective survival may be expected with the administration of chemotherapy with drug loss from the start of treatment.

In all our patients, because the ALP levels had already been elevated to more than 2.5 times the ULN, HAIC was continued until this level was within 1.5 times the ULN; this ALP value (≥ 2.5 times the ULN) came under grade 2 of the National Cancer Institute Common Terminology Criteria for Adverse Events, version 3.0. Elevated ALP (≥ 2 times the ULN) is one of the factors associated with poor prognosis in metastatic colorectal cancer patients treated with 5-FU, oxaliplatin, or oxaliplatin [15, 16]. In our patients, the mean ALP levels decreased from

969.3IU/l to 422IU/l due to shrinkage of the liver metastases after only 3 consecutive HAIC cycles. Standard systemic chemotherapy was initiated after the HAIC-mediated improvement in liver function because the abovementioned meta-analysis evaluation revealed that HAIC does not improve patient survival over that achieved with systemic chemotherapy [8–10].

It might have been possible to safely initiate systemic chemotherapy in our patients without prior HAIC. However, if standard systemic chemotherapy had failed because it could not be completed (*e.g.*, incomplete administration or administration with drug loss), further treatment might have been impossible because of the progression of advanced liver metastases. The combined use of HAIC and standard systemic chemotherapy in patients with highly advanced liver metastases seems to effectively facilitate the administration of subsequent systemic chemotherapy without drug loss. In order to prove that our treatment strategy may be a viable treatment option for such patients, it is necessary to accumulate more cases in multicenter and to determine the success rates and/or responses as well as possible adverse events.

In conclusion, we safely administered FOLFOX without drug loss in 3 patients with highly advanced unresectable liver metastases from colorectal cancer after the improvement in liver function caused by the shrinkage of liver metastases due to prior HAIC.

References

1. Weitz J, Koch M, Debus J, Höhler T, Galle PR and Büchler MW: Colorectal cancer. *Lancet* (2005) 365: 153–165.
2. Tournigand C, André T, Achille E, Lledo G, Flesh M, Mery-Mignard D, Quinaux E, Couteau C, Buyse M, Ganem G, Landi B, Colin P, Louvet C and de Gramont A: FOLFIRI followed by FOLFOX6 or the reverse sequence in advanced colorectal cancer: a randomized GERCOR study. *J Clin Oncol* (2004) 22: 229–237.
3. Grothey A, Sugrue MM, Purdie DM, Dong W, Sargent D, Hedrick E and Kozloff M: Bevacizumab beyond first progression is associated with prolonged overall survival in metastatic colorectal cancer: results from a large observational cohort study (BRITE). *J Clin Oncol* (2008) 26: 5326–5334.
4. Fakih MG: 5-fluorouracil, leucovorin and oxaliplatin (FOLFOX) in the treatment of metastatic colon cancer with severe liver dysfunction. *Oncology* (2004) 67: 222–224.
5. Arai Y, Inaba Y, Takeuchi Y and Ariyoshi Y: Intermittent hepatic arterial infusion of high-dose 5FU on a weekly schedule for liver metastases from colorectal cancer. *Cancer Chemother Pharmacol* (1997) 40: 526–530.
6. Link KH, Sunelaitis E, Kornmann M, Schatz M, Gansauge F, Leder G, Formentini A, Staib L, Pillasch J and Beger HG: Regional chemotherapy of nonresectable colorectal liver metastases with mitoxantrone, 5-fluorouracil, folinic acid, and mitomycin C may prolong survival. *Cancer* (2001) 92: 2746–2753.
7. Kemeny NE, Niedzwiecki D, Hollis DR, Lenz H, Warren RS, Naughton MJ, Weeks JC, Sigurdson ER, Herndon II JE, Zhang C and Mayer RJ: Hepatic arterial infusion versus systemic therapy for hepatic metastases from colorectal cancer: a randomized trial of efficacy, quality of life, and molecular markers (CALGB 9481). *J Clin Oncol* (2006) 24: 1395–1403.
8. Mocellin S, Pilati P, Lise M and Nitti D: Meta-analysis of hepatic arterial infusion for unresectable liver metastases from colorectal cancer: the end of an era? *J Clin Oncol* (2007) 25: 5649–5654.
9. Harmantas A, Rotstein LE and Langer B: Regional versus systemic chemotherapy in the treatment of colorectal carcinoma metastatic to the liver. Is there a survival difference? Meta-analysis of the published literature. *Cancer* (1996) 78: 1639–1645.
10. Meta-Analysis Group in Cancer: Reappraisal of hepatic arterial infusion in the treatment of nonresectable liver metastases from colorectal cancer. *J Natl Cancer Inst* (1996) 88: 252–258.
11. Iguchi T, Arai Y, Inaba Y, Yamaura H, Sato Y, Miyazaki M and Shimamoto H: Hepatic arterial infusion chemotherapy through a port-catheter system as preoperative initial therapy in patients with advanced liver dysfunction due to synchronous and unresectable liver metastases from colorectal cancer. *Cardiovasc Intervent Radiol* (2008) 31: 86–90.
12. Arai Y, Takeuchi Y, Inaba Y, Yamaura H, Sato Y, Aramaki T, Matsueda K and Seki H: Percutaneous catheter placement for hepatic arterial infusion chemotherapy. *Tech Vasc Interventional Rad* (2007) 10: 30–37.
13. Therasse P, Arbuck SG, Eisenhauer EA, Wanders J, Kaplan RS, Rubinstein L, Verweij J, Van Oosterom AT, Christian MC and Gwyther SG: New guidelines to evaluate the response to treatment in solid tumors. *J Natl Cancer Inst* (2000) 92: 205–216.
14. Chu E and Devita VT: Concept of dose intensity; in Cancer, Devita VT, Hellman S, and Rosenberg SA eds, 7th Ed, Williams & Wilkins, Baltimore (2000) pp 300–301.
15. Bensmaïne MA, Marty M, de Gramont A, Brienza S, Lévi L, Ducreux M, François E, Gamelin E, Bleiberg H and Cvitkovic E: Factors predicting efficacy of oxaliplatin in combination with 5-fluorouracil (5-FU) ± folinic acid in a compassionate-use cohort of 481 5-FU-resistant advanced colorectal cancer patients. *Br J Cancer* (2001) 85: 509–517.
16. Mitry E, Douillard JY, Van Cutsem E, Cunningham D, Magherini E, Mery-Mignard D, Awad L and Rougier P: Predictive factors of survival in patients with advanced colorectal cancer: an individual data analysis of 602 patients included in irinotecan phase III trial. *Ann Oncol* (2004) 15: 1013–1017.