

Acta Medica Okayama

Volume 12, Issue 3

1958

Article 9

OCTOBER 1958

The morphological study of blood vessels in cervical carcinoma (Three-dimensional study by reconstruction models)

Shotaro Sugihara*

*Okayama University,

Copyright ©1999 OKAYAMA UNIVERSITY MEDICAL SCHOOL. All rights reserved.

The morphological study of blood vessels in cervical carcinoma (Three-dimensional study by reconstruction models)*

Shotaro Sugihara

Abstract

With a view to study the blood vessel construction in cervical cancer the author prepared the reconstruction models and the results to be described below were obtained by three-dimensional observations carried on the models. 1. The arteries in the surrounding tissues of cancer are markedly proliferated, and in the surrounding tissues they present the formation of blood-vessel bands. 2. The spiral formation or corkscrew-like formation presented by blood vessels in the bands in the surrounding tissues of cancer seems to be the characteristic of arteries. 3. As for the direction of flow of arteries in the tissues surrounding cancer, the arteries in the normal case generally run slanting towards the surface of the cervix in the direction of the periphery, but the arteries in the surrounding tissues of cancer run towards the cancer tissue. 4. Apart from mother blood vessels, the blood vessels in the cancer tissue all present an imperfect capillary-like construction and there is none that possesses the normal arterial or venous construction. Some part is dilatated and other part is narrow, suggesting an incomplete blood supply. The direction of the flow is also irregular. Mother blood vessels grow rapidly large once they are taken into the cancer tissue. 5. All blood vessels other than the mother vessels reveal an imperfect capillary-like construction in the cancer tissue, and in places the walls of these blood vessels are indistinct; and consequently it is but natural that they bleed so easily.

Acta Med. Okayama 12, 261—280 (1958)

**The Morphological Study of Blood Vessels in Cervical Carcinoma
(Three-Dimensional Study by Reconstruction Models)**

Shotaro SUGIHARA

*Department of Obstetrics and Gynecology Okayama University Medical School
(Director : Prof. Hideo Yagi)*

Received for publication, August 2, 1958

It goes without saying that the blood vessels supplying nutrition to normal tissue naturally behave differently when a cancer develops in such a tissue. Namely, it is reasonable to assume that there is some relationship between the freely growing cancer and blood vessels controlling the cancer tissue as this energy source and playing an important role in the changes of mother tissue, especially of the cell growth. By colposcopic findings changes in the blood vessels can clearly be recognized already at an early developmental stage of cancer. In other words, the influence of the cancer tissue on blood vessels and the reaction of the blood vessels to the cancer tissue seems to be characteristic phenomena even at an early developmental stage. It seems to be extremely interesting to study the changes brought about by cancer tissue to the blood vessels of adjacent mother tissues and the blood vessel morphology in the cancer tissue itself and also to investigate the causal factors of uterine bleeding constituting the main complaint of patients suffering from cervical carcinoma. Therefore, with these points in mind the author conducted a study on patients with cervical carcinoma. As regards cancer and blood vessels it is true that there are numerous reports on such studies up to the present, but the majority of them are histological studies and results of plane observations. In view of this the author prepared the reconstruction models of cervical cancer blood vessels from the hysterectomized specimens and studied the cancer and the changes in blood vessels by carrying out three-dimensional observations on blood vessels of the cervix. In addition, the findings of cervix in the present study were compared with the colposcopic findings, and the results of which are described in the following.

MATERIALS AND METHODS

Materials for the investigation of normal cervical blood vessels were obtained from the following patient :

Case Abstract on M.O. (55 years old)

Main complaints were hypermenorrhea and irregular bleeding.

History : she was born healthy and had on history of illness — menarche at 14 years 3 months — thereafter continued to have a regular 28-day type of menses for the duration of three days with a slight lower abdominal pain just before the onset of menses, otherwise showing no disturbances whatsoever. Married at the age of 18 years and 6 months. Her husband died when she was 42 years old. She had no record of pregnancy nor delivery. From about October 1954 she began to have hypermenorrhea — from the beginning of October 1955 she recognized irregular bleedings mixed with blood clots following menses, but she experienced neither pain nor any other disturbances.

Present conditions : physique and nutrition — intermediate; apart from a slight tendency of anemia, no marked changes can be observed physical examinations. *Local findings* : retroversion of uterus, the size normal but no mobility — adnexa on both sides of the uterus are normal — the cervix also normal — *diagnosis* : adhesive retroversion of uterus with functional bleeding. For this the hysterectomy was performed on October 25, 1957.

Findings at operation : the uterus — retroflexion and as big as a large-sized goose egg; the degree of hardness — elastic but hard; the adhesion of the posterior wall of uterus to the sigmoid and inflammation surrounding both oviducts, but no other disorder can be recognized. Abdominal radical hysterectomy was completed in one hour and 15 minutes. *Postoperative diagnosis* : submucous myoma — histologically it was likewise uterine myoma. This hysterectomized uterus specimen was fixed for one week and excising the posterior edge of the cervix of uterus, a specimen of 1.0cm × 0.3 × 0.3cm in size was prepared according to the method described in the section of METHOD.

For the investigation of the blood vessels in cervical carcinoma the material described in the following was used :

Case Abstract on K.K. (23 years old).

Chief complaints : Irregular bleeding and metrorrhagia. *History* : She was healthy from birth and had no history of illness. Menarche — 16 years old, and ever since she had a regular menstrual cycle of 30-day type lasting three days, and had no menstrual disorder. The first marriage at the age of 19 years and 4 months, and the second marriage at the age of 23 years and 2 months, and has maintained that marital state up to the present. No history of pregnancy and delivery. She had a slight amount of irregular bleeding once in the end of January and another in the end of April, 1956. From the beginning of March 1956 she began to have leukorrhea with offensive odor, but had experienced no pain nor any other disorder.

Recent conditions : Physique and nutrition — intermediate; physical examinations — no marked changes in the chest and abdomen; local findings — anteversion of uterus; the size — normal, and mobile. As for the adnexa no abnormality apart from the right side giving the cystoma-like impression on touching. As for the parametrium, a slight infiltration on the left side but no infiltration in the right. The cervix is normal in size; but the posterior edge of cervix revealed cancerous erosion. Diagnosis was cervical carcinoma in the second stage. She was operated on for it on May 11, 1957.

Findings at operation : Uterus — anteversion and normal in size; the degree of hardness — normal. The oviducts on both sides had tubal edema with inflammation around the ovaries and corpus luteum was found in the left ovary. Although

there was no infiltration in the right side of the parametrium, in the left side there was a lymph node as large as the tip of thumb, attached to the pelvic wall.

Postoperative findings : On account of the infiltration into the parametrium it was diagnosed as cervical carcinoma in stage II and histologically it was squamous cell carcinoma (matured to an intermediate degree). The cervix taken from this hysterectomized uterus was fixed from one week by the method described elsewhere in the section of method; and the specimen was cut at the boundary between the macroscopic cancerous erosion and normal tissue into a piece of $1.0\text{cm} \times 0.3 \times 0.3\text{cm}$ in the same manner as in the same manner as in the case of the normal one.

Methods : These two uteri to be used as the experimental materials are fixed in a 10% formalin solution immediately after hysterectomy, and after one week the cervix of the uterus is taken out. In order to prepare specimens in as much the same condition as possible both the normal and cancer cervixes are cut at the center of the posterior edge of the cervix as the center into an oblong block in such a way that the cervical mucous membrane is on the surface. Such a piece of tissue of respective cervixes is washed by water, dehydrated and embedded in paraffin according to the conventional method; and serial sections in the thickness of 10μ each are prepared by cutting at right angle to the surface of cervix starting from the vicinity of cervix toward the orifice of uterus. These sections are stained with Hematoxylin-Eosin and WEIGERT elastic fiber staining. These serial microscopic sections are photographed by an EIKON camera for slides focusing on the cross-section of blood vessels and the blood vessels at the magnification $\times 100$. Precise lines of blood vessel pictures are established and these blood vessel pictures are copied by impressing them on the wax sheet 1 mm in thickness, and the impressions are cut out. Piling these one on top of another in the proper serial order, the three dimensional reconstruction models are constructed with the base lines as the criteria.

The most important point in reconstructing such models is to establish a base line. For this the author employed two methods. Namely, the one is to carve out three fine triangular grooves on the surface of the cervix tissue block parallel to one another and make these temporary base lines; and the other method is to pass two needles with string soaked in Indian ink through the cervix tissue block in parallel to the surface and get temporary base lines of Indian ink. The temporary base lines as the basis precise base lines are established at magnification $\times 100$. Next, as for the diameter of blood vessel that portion of the cross-section of blood vessel that is as much round as possible is selected, and by using a sliding micrometer possessing Vernier of $1/20\text{mm}$, the diameter is measured at the right angle to the direction of the blood vessel, and from this the true

value of the diameter is calculated. As for the area of the cross-section of blood vessel, the cross-section of a blood vessel which was magnified 100 folds is copied on a graph paper with 1 mm gradings, and is computed by counting the number of squares of gradings included in the copied cross-section picture. From this an approximate area of the cross-section is computed.




Fig. 1




Fig. 2

EXPERIMENTAL RESULTS

The blood vessel construction in the normal cervix : Reconstruction models are 19 cm high \times 15 cm \times 25 cm as shown in Fig. 1 (the frontal view) and Fig. 2 (the lateral view). Since these models are prepared with serial sections cut at the right angle to the surface of cervix starting from the posterior edge of the cervix to the orifice of uterus and magnified, this model represents a portion of the blood vessel construction running from the vicinity of the cervix toward the exterior uterine orifice. Namely, the lower part is the region adjacent to the cervix, the upper part represents the region of uterine exterior orifice, and the front the surface region of the cervix. As for the arteries and veins, the maximum diameter of artery is 70μ , the minimum 20μ , and the maximum diameter of veins is 500μ and the minimum 30μ .

Taking up the arterial findings at first, there are six arteries in this model. Supposing these 6 arteries are designated as A, B, C, D, E, and F, and describing each in details, three arteries, 70μ , 50μ , and 50μ in size, run upward for the distance of 0.1 mm and are anastomosed into a single artery; and from this anastomosed artery branch arteries A, C, D, and E are spreading out, but arteries B and F run out singly without ever anastomosing within this model. The artery A is seen branching out directly from the anastomosed joint as a branch 50μ in size without sending out any branch nor anastomosing with any peripheral vessel, and runs not in parallel but towards the surface of cervix and diagonally in the direction of the exterior orifice of uterus. The distance between the base of the model to the cervix surface differs from the same at the periphery, and such a distance gets shorter as it approaches the periphery. As for the direction of blood vessels, instead of spiral form they run in smooth undulation towards the periphery. The artery A has the vascular width of 30μ at 0.92 mm from the anastomosed joint. As for the artery B, it has the vascular diameter of 40μ , and runs diagonally through the networks of veins without anastomosing or branching in the direction of the exterior orifice of uterus, making smooth undulation, and it has shrunk down to the diameter of 20μ at the point about 0.6 mm above the base. Two branches with vascular diameter of 50μ and 40μ , running across the network of veins for 0.4 mm, are anastomosed with each other, forming an artery with the diameter of 70μ , and then it sends out three branches, C, D, and E. The artery C is 40μ at the point where it is branching out but at 0.49 mm distance it is only 30μ . This branch runs approximately in the same fashion as other vessels in the

model, running diagonally through the network of veins in a smooth undulating form just like the artery A.

Arteries E and D are branches with vascular diameter of 40μ at the joint but they become slenderer arteries of 20μ at the distance of 1.41 mm from the joint. Both D and E arteries, after branching out from the joint, run toward the surface of cervix in an undulating form without anastomosis or branching and terminate in the network of veins. The artery B, on the other hand, is completely independent of other five arteries, and has the vascular diameter of 20μ , but it grow down to an artery with a diameter of 15μ at 0.18 mm away.

As for the distribution of veins, differing from that of arteries no vein runs singl, but all of them anastomose somewhere and then send out branches, and consequently it is impossible to count exact number and precise direction. However, what appear to be main trunks in the model are three veins with vascular diameter of $200\text{--}150\mu$, $150\text{--}120\mu$, and 50μ ; and these three veins are branching out from a vein with the diameter of 200μ . The venous branches are coming mainly from these three trunks and each in turn sends out branches in a tree-like form, thus making complicated networks of veins. One thing is, however, clear, that is, every one of them anastomose and sends out branches, forming rather uniform networks of veins. All of them at first run almost right angle to the surface of cervix, and gradually approaching the cervix surface then run diagonally in the direction of exterior orifice of uterus.

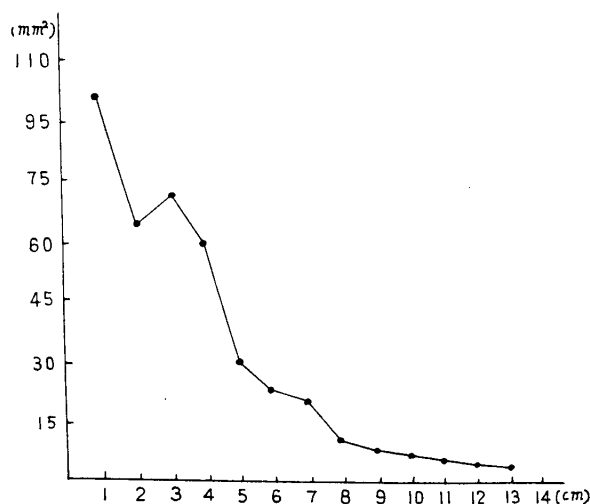


Table. 1

Blood Vessels in Cervical Carcinoma

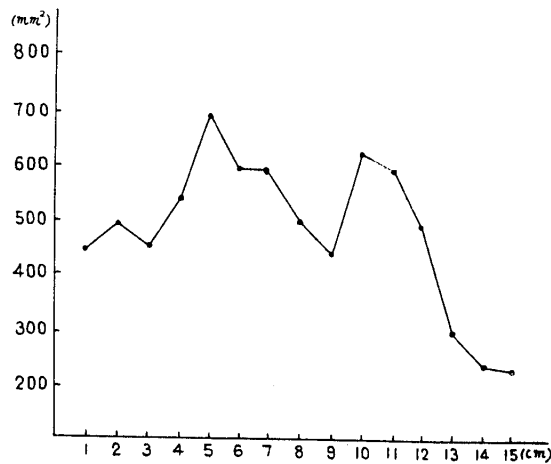


Table. 2

Now, presenting the area of the cross-section of blood vessel, every one centimeter as a unit from the vicinity of the cervix to the exterior orifice of uterus, it is shown in Table. 1 (artery) and Table. 2 (vein). Firstly, the area of the cross-section of artery grows rapidly smaller as it approaches the periphery, but it is wider at about 3 cm from the vicinity of cervix. This is due to the increase in number of arteries at this region by branching of four arteries into seven arteries with subsequent increase in the area of cross-section. Veins are not quite so simple as arteries, and gradually they begin to possess many projections and grow less in number as they approach the periphery. In other words, the area of the cross-section of veins in the network of venous capillaries is also small.

The blood-vessel construction in cervical carcinoma : The reconstruction model is shown in Fig. 3 (frontal view) and Fig. 4 (lateral view), and it is about 15 cm in height and 24 cm \times 24 cm wide. As for the perspectives of the model, this was prepared with serial sections cut right angle to the surface of cervix at the posterior lower edge of the cervix. The base of the model is the region surrounding the cervix, and the upper part represents the exterior orifice of the uterus. The front is the surface of cervix, which is represented by wire as shown in plates.

With the purpose to make a comparative study of changes in the blood vessel construction of normal tissue and cancer tissue of the cervix, the model was made by obtaining tissue cut out from the border region between the cancer tissue and normal tissue. For the explanation of this




Fig. 3




Fig. 4

model, therefore, it is divided into two parts, namely, no-cancerous tissue blood vessels in the tissues surrounding cancer and cancer tissue blood vessels.

At first the findings on the blood vessels in the tissue surrounding cancer will be explained. The blood vessels nearer to cancer differ definitely in their construction from those located a little farther away from cancer even in the tissue surrounding cancer. As for the findings of arteries, we observed 6 arteries in the case of normal cervix, but in this case there are many more arteries. As there are hardly nay vessels running singly, it is difficult to count the exact number of arteries in this

case. Arteries increase in number as they approach nearer to the cancer tissue and again they decrease as they come in contact with cancer tissue. Namely, a marked change can be observed between the blood vessels in the tissue nearer to cancer and those in the tissue a little farther away. Diameter of arteries in the latter tissue is about $100-80\mu$, but it becomes gradually smaller as the arteries approach nearer to cancer. Number and density of arteries also greatly increase in the surrounding tissue as compared with those in normal tissue, forming bands of blood vessels in the vicinity of cancer. In this region anastomoses and branches being quite complicated, needless to say there are no vessels running singly. Diameter of blood vessels in the tissues touching the cancer tissue is decreased in size from $100-80\mu$ down to $20-30\mu$ and finally growing so small they can no longer be recognized as arteries. Here the number of arteries decreases by degree, and branching as well as anastomosing become more simple, and now some of them run singly, at last running in the form of terminal arteries.

Although arteries in normal case generally run in line with the surface of cervix towards the periphery, in this reconstruction model arteries showing no definite order and growing smaller and smaller, most of them run towards the cancer tissue and to the periphery, namely, into the cancer tissue where practically they can no longer be recognized as arteries. Of course, these are small arteries as slender as with vascular diameter of $20-30\mu$.

Next, it seems to be the characteristic of arteries in this model to show spiral formation, the structure specific to these arteries. The structure of normal cervical arteries is of a slow undulating form as observed in normal case, but in the present cancer case arteries are spiraled sharply, especially those in the tissue close to cancer tissue show a corkscrew-like spiral formation. The twist of such a spiral grows less sharp in the tissue farther away from cancer tissue. In other words, conversely arteries $100-80\mu$ in diameter gradually grow slenderer at the same time the twist of spiral becomes sharp, and branching as well as anastomoses grow more complicated, and growing slender and slender they run towards the cancer tissue.

As for the findings on veins, there are what seem to be trunk veins and many small veins branching from them. These veins become denser as they come nearer to the cancer tissue, and presenting no fixed order in their direction, they do not show any normal form of branching like the branching of a tree. The diameter of these veins with exception of trunk veins is about $100-20\mu$ and just as veins approach the cancer

tissue. Next, those what might be considered as trunk veins have at first vascular width of 170μ but as they approach the cancer the diameter, instead of getting slender, grows bigger until finally they have the diameter as big as 350μ . The trunk veins increase in vascular diameter as they approach the cancer tissue, presenting a picture just the reverse of those in normal case; but these trunk veins at the periphery are taken in the cancer tissue where they are transformed into cancer tissue veins.

Now, coming to the blood vessels in the cancer tissue, most of blood vessels are capillaries in their construction and these are very difficult to distinguish arteries from veins and there are hardly any arterial construction observable in the cancer tissue. Furthermore, veins present more of capillary construction rather than venous construction. It goes without saying that no venous construction as observable in this model can at all be recognized in the cancer tissue.

Veins in the cancer tissue present the capillary construction as mentioned above, and there are hardly any veins possessing the normal venous construction. The majority of them do not reveal the usual vessel construction with a single sinus but the vessel has the parts swollen and other parts narrow, revealing a picture morphologically difficult to recognize as the blood vessels. As for the vascular diameter, the big parts are 130μ and narrow parts less than 20μ , but vessels are generally slender, showing none of the branch formation of a tree as encountered in the normal cervix but disorderly construction. Even in their direction unlike those in the normal case they never grow slenderer by branching out as they approach the distal part. Some are slender even in the proximal part, and likewise some have a big vascular diameter even in the distal part.

In the cervical carcinoma the blood vessels in cancer tissue are situated quite closely to the surface of the cervix, presenting a picture as if they are directly on the surface. Namely, they are located very closely to the surface layer of the cervix, and the loss of the epithelium is of course responsible for this phenomenon. Although fairly large veins can be recognized, by microscopic observations they do not present the normal venous construction as has already been mentioned, but revealing a vascular sinus with thin wall consisted of simple mesodermal cells, in places there are vessels whose sinus is hardly distinguishable, and in such places numerous erythrocytes are scattered around. Therefore, the nutrition in the cancer tissue seems to be supplied not only by indigenous vessels but also by numerous regenerated vessels.

Mother vessels what might be considered as trunk vessels have at

first the vascular diameter of 170μ , but as they are absorbed into the cancer tissue, they grow well over 350μ . Unlike those in the normal case in which trunks grow gradually slenderer as they approach the periphery, these mother vessels on the contrary get larger as they are taken into the cancer tissue. With respect to the quantity of blood vessels, they are less dense in the cancer tissue as a whole, but in the interstitium of the cancer tissue more blood vessels are recognized than those in normal case, thereby showing an abundant blood vessel distribution there.

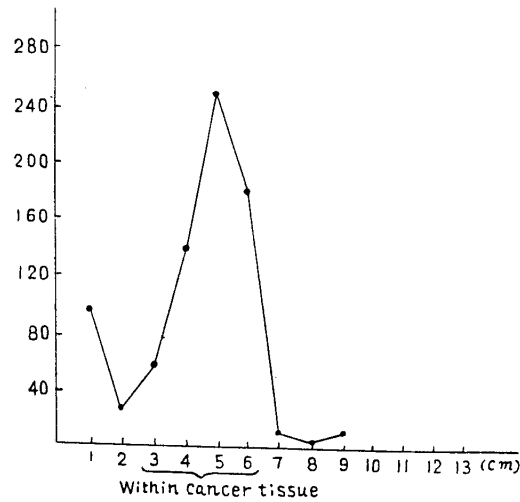


Table. 3

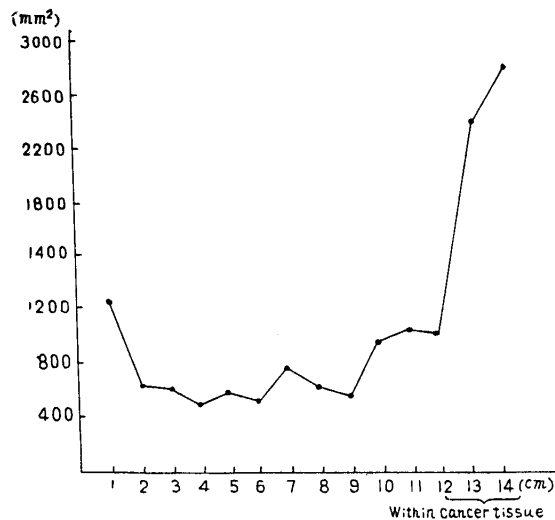


Table. 4

In indicating the area of blood-vessel cross-section (in a unit area) from the surrounding region of the cervix to the exterior orifice of uterus at the distance of 1 cm each, it may be represented as in Table 3 (artery) and Table 4 (vein). Table 3 represents the area of the artery cross-sections, and at about 2.2 cm it rapidly increases and reaches its maximum at 4.2 cm, decreasing rapidly thereafter. In other words, the area of cross-sections of artery increases rapidly in the tissue surrounding the cancer but it rapidly decreases as the artery approaches the cancer tissue and finally it is lost. Table 4 represents the cross-sections of the vein, and up to 9 cm it assumes more or less a similar curve, but thereafter instead of decreasing it increases rapidly. Namely, the area of cross-sections in the case of the vein increases gradually as the vein approaches the cancer tissue, and it continues to increase even after entering into the cancer tissue.

DISCUSSION

So long as there exists a vital function, a circulation of nutrition as the energy source is indispensable. From this point of view it seems the study on the relationship between tumor and blood vessels becomes all the more important.

Because of the very fact that a tumor possesses a specific characteristic to grow unlimitedly independent of the mother tissue, it demands an excessive amount of nutrition; and hence a great interest has been focused on the actual construction of these blood vessels supplying nutrition to tumor. Actually there are many literatures dealing with this problem. And this problem may be divided into two parts. Firstly, for the purpose of clarifying any significance the blood vessel distribution may have for tumor there are reports by FUJIWARA¹, OSHIMA², KOUKETSU³, HORIUCHI⁴, KOCHI⁵, GREISCHER⁶, MIDANA⁷, HATTORI⁸, and SUZUE-NAGASE⁹, in which they studied the effects of the ligation or severance of blood vessels on the growth and proliferation of a tumor. Secondly, what pathological changes would be brought upon the blood vessel distribution or the blood vessels themselves in a tumor in the course of the growth and proliferation of the tumor.

In the present experiment the author dealt with the second problem, changes in blood vessels in cancer, namely, the changes of blood vessels both in the tissues surrounding cancer and in the cancer tissue itself. Many reports on this problem are also available, but most of them are the results of roentgen observations or of histological investigations.

However, it is impossible to study the peripheral blood vessels by roentgen observations, and it is quite difficult to make a three-dimensional study by histological investigation. For these reasons with a view to carry out three dimensional observations the author studied, using reconstruction models, the changes of blood vessels brought about by cancer.

At first the reconstruction model of a normal case used as the control will be discussed, and then the reconstruction model of the cancer case will be described. Concerning normal cervical blood vessels there are results of studies from the standpoints of anatomy as well as of gynecology and obstetrics. Particularly in the study on the changes of blood vessels caused by pathological changes of the uterus the normal cervical blood vessels are usually taken as the control. In the present investigation the author used the same as the control. First of all, both arteries and veins of the cervix as a whole are arranged in a funnel shape in the direction of the exterior orifice of uterus. As for the arteries, every artery distinctly presents a funnel shape and as for the veins although each does not show the clear funnel shape individually owing to its branching and anastomosis, these veins as an entity like-wise present a funnel shape with a tendency to run down in the direction of the exterior orifice of uterus. There are also roentgenological studies by SAITO¹⁰, HIRATAKE¹¹, ITO¹², NISHI¹³, and REDLICH¹⁴, and roentgenological and histological studies by KAWANISHI¹⁵, and anatomical studies by HYSTL¹⁶, and STELLIO-V-SKAMNAKIS^{17,27}, on the funnel-shaped cervical blood vessels; but all of them deal only with arteries. Arteries, never running singly, go to the periphery after presenting complicated branches and anastomoses in the form of branches of a tree. The area of cross-section of veins, as shown in Table 4, gradually decreases and veins themselves grow slenderer as they approach the periphery. SAITO¹⁰, HIRATAKE¹¹, KAWANISHI¹⁵, and ITO¹², state that these run in an undulating formation, while REDLICH¹⁴, HYSTL¹⁶, and NISHI¹³, claim that these vessels present a spiral form in multipara but in nullipara women they do not show the spiral form. In the present study even in nullipara women although the arteries show no twisting like a spiral, they are in an undulating formation. Moreover, in the present case apart from the branching and anastomosing at three points, six arteries reveal relatively little anastomoses.

As already mentioned, when a certain stimulation occurs in tissue, naturally changes appear in blood vessels, but in the case of KREYBERG^{18,19,20} he recognized circumscribed dilatation of small blood vessels accompanied by a highly accelerated exude in the mice smeared with tar. Namely, he stated the evidence of dilatatory changes in capillaries. Ac-

According to HINSELMANN²¹, LEWIS, SHEFFEY, BOLTON, and LANZ²², and IWAZU²³ marked changes can be recognized in the blood vessels of cancer even at an early stage by colposcope. It is understandable that the blood vessels in the tissue with a tumor growth would behave differently from those under normal condition in the mother tissue. Namely, in the colposcopic findings LEWIS et al²². and IWAZU²³ state that the blood vessels in cancer present a characteristic picture : i. e. in the cancer tissue blood vessels are big and numerous, but the direction of flow shows a specific irregular pattern and an abrupt ending. KAWANISHI¹⁵ states that those blood vessels in the degenerated tissue adjacent to the cancer histologically reveal marked dilatation and proliferation at an early developmental stage, and that also numerous regenerated blood vessels can be recognized. Both GOLDMANN^{24,25,26} and STELLIO-V-SKAMNAKIS^{17,27} claim that there occurs an active regeneration of the blood vessels in the surrounding tissue of cancer. Even in the model studied by the author a marked increase can be seen in the number of blood vessels, especiall of arteries, as compared with those in the control.

As for the arteries in this model also many arteries with diameter larger than that in the normal are seen running in the direction of cancer tissue, and their diameter, gradually growing slenderer in the proximity of the cancer tissue, they send out numerous branches and become capillaries. Even around the cancer capillarylike fine arteries suuound the cancer tissue; and these also grow smaller and smaller as they approach the cancer tissue; and neither branching nor anastomosing but decreasing in number by derees, they run in the direction of cancer and finally present a picture of terminal arterial capillaries.

This pattern of arterial flow is specific as compared with that of normal arteries. KAWANISHI¹⁵, GOLDMANN^{24,25,26}, and STELLIO-V-SKAMNAKIS^{17,27} recognized such regeneration of blood vessels in the tissues surrounding cancer. Concerning these regenerated networks KAWANISHI¹⁵ and GOLDMANN^{24,25} state that these networks of blood vessels are formed not only for the sole purpose of supplying the nutrition to the cancer tissue but in all probability also for the protection against toxic substances invading this region. TANAKA²⁸ concurs with the opinions of the above two in that he considers this regeneration as a kind of granulation tissue. It is obvious that blood vessels grow more numerous to play the role of the nutrient pathway on the advent of a cancer growth in tissue. This phenomenon can also be recognized in the model : i. e. many comparatively large vessels are seen growing in the surrounding tissues which send out vigorously many branches in the direction cancer, thus forming

numerous networks. However, close to the cancer tissue branches and anastomoses of these numerous networks grow less and less and they finally present a picture of terminal arteries. If they are solely suppliers of nutrition, they would naturally enter into cancer in a large number as they are without diminution in number so as to send an abundant blood, but actually they behave in the manner just described. Therefore, it seems that apart from the role of blood suppliers, they have a certain other action, perhaps a reaction against cancer or a protective action.

In their colposcopic findings LEWIS, SHEFFEY, BOLOTN and LENZ²² state that the blood vessels in cancer are arranged in a corkscrew formation (the so-called adaptive hypertrophy) and that this blood vessel change is most significant. Again in his observation on the blood vessels at the onset of cancer growth GOLDMANN²⁶ states the order of blood vessel construction is immediately broken, bringing about a great irregularity in the circulatory system, as a kind of vessels specific to the regenerated vessels they present an irregular corkscrew-like bending. Arteries, as mentioned already in the normal case, essentially present an undulating formation, but in the case of cancer their twisting is sharper like a spiral. And this twisting grows more pronounced as vessels approach closer to cancer, but the diameter of vessels grows smaller while their branches more numerous. This appears to be active developmental course taken by arteries in the face of a very urgent demand for supplying blood to the cancer tissue. HINSEAMANN²¹ likewise considers that the change of the blood vessels in cancer is not only a passive change due to the cancer infiltration, but also it is an active developmental course taken by the vessels. Veins like arteries grow denser in the proximity of cancer and bigger than those in the normal case, and this coincides with the findings of various investigators. Moreover, the direction and manner of branching have no fixed regularity and these findings also agree with the colposcopic findings.

As for the blood-vessel construction within the cancer tissue, in the reconstruction model hardly any arterial construction can be recognized, but they present a capillary-like construction. As far as the blood vessels in the cancer tissue are concerned, there are none that can be distinguished as arteries; and apart from the veins of mother blood vessels they are all regenerated vessels possessing a capillary-like construction.

The density blood-vessel distribution in the cancer tissue is greater than in the control as shown in Table 4. Relative to this point, although when blood vessels in the adjacent interstitium are included, total blood vessels are extremely great in number. KAWANISHI⁵ also in his histologi-

cal comparison recognizes a greater distribution of blood vessels in the interstitium than that in the normal tissue. Although STELLIO-V-SKAM-NAKIS^{17,27}, HIRATAKE¹¹, ITO¹², and LEWIS²⁹ state that the blood vessels distributed in the cancer tissue are extremely small in number, such a finding is the result of their experimental technique in which they studied mainly arteries. The total blood vessels distributed in the cancer tissue and surrounding tissues are extremely numerous as mentioned already. Moreover, the manner of branching and the direction of flow of the vessels in the cancer tissue have no fixed order but irregular and complicated. LEWIS, SHEFFEY, BOLTON, and LANZ²², IWAZU²³, and HINSELMANN²¹, point out this as the characteristic colposcopic finding. In his observation on the blood vessels in cancer with the use of reconstruction models, SHINOHARA³⁰ states that in the cancer tissue besides the indigenous blood vessels there usually are capillary-like vessels with irregular and complicated branches and anastomoses, forming networks more complicated in their structures and different from the direction of the flow of normal blood vessels. As shown in Table 4 the blood vessels in cancer demonstrate to have their cross-section area in unit area greatly increased: the diameter of the mother vessels is 170 μ at first, but gradually increasing, it finally reaches twice the original diameter, as much as 350 μ in cancer in this model.

By colposcope IWAZU²³ recognizes that blood vessels in cancer to have grown bigger, and in the present model these mother blood vessels grow quite large. Next, as for those blood vessels in cancer, possessing capillary-like construction, most of them do not reveal the form with a simple individual sinus, but they present a construction, dilatated at one point while narrow at another point and difficult of recognizing as blood vessels. TANAKA³⁸ gives similar findings, and Ribbert also puts an emphasis on this point; and they propose a cancer nutritional impediment theory by saying that the circulation is markedly delayed by this unusual construction of blood vessels. SHINOHARA³⁰, KUROIWA³², and LEWIS²⁹ also found numerous vessels with capillary-like construction, partly dilatated and partly constricted. In their comparative studies on the oxygen content in the venous blood of cancer tissue and in the normal venous blood Bierman, Kelley and Singer state that the oxygen content in the cancer blood is greater and the difference in the oxygen contents between the arterial blood and the venous blood, entering into cancer, is smaller than the difference between artery and vein in regions other than cancer. They claim that this is due to the damaged capillary bed where there is no complete capillary construction but there are sinus-like dilatation and abnormal

communications between arteries and veins. YOSHIDA³⁴ and KIN³⁵ contend that there are two kinds of blood vessel constructions in the cancer tissue; vessels (mother blood vessels) with the complete shape, and blood passages with incomplete construction, namely, those that pass the spaces between connective tissues or spaces between cancer cells. The same is true in the case of the author's model, i. e. apart from mother blood vessels, there can be recognized a simple sinus formed by mesodermal cells, and in places on distinct sinus can be distinguished but numerous blood cells scattered all around. In any case it is evidently clear that apart from that of mother vessels, the blood vessel construction in cancer tissue potends of an imperfect blood supply.

As for the bleeding tendency of the cancer tissue, MATSUI³⁷, KIKUCHI^{38,39,40}, TAKAI⁴¹, ITO⁴², and FREUND⁴³, all claim that the arteries are less affected by cancer cells but veins are the ones mainly infiltrated by cancer cells, and consequently the bleeding in the cancer tissue is due chiefly to the venous bleeding. As has already been described in the present study, with exception of the mother vessels possessing the normal venous construction the majority of other vessels in the cancer tissue, having no normal construction, can be recognized only as a sinus, and even this is an imperfect sinus formed by mesodermal cells. In places some of them do not clearly show even the sinus, presenting the incomplete blood passages as mentioned by YOSHIDA³⁴ and KIN³⁵; and from these conditions an easy tendency of bleeding in the cancer tissue can be understood.

SUMMARY

With a view to study the blood vessel construction in cervical cancer the author prepared the reconstruction models and the results to be described below were obtained by three-dimensional observations carried on the models.

1. The arteries in the surrounding tissues of cancer are markedly proliferated, and in the surrounding tissues they present the formation of blood-vessel bands.
2. The spiral formation or corkscrew-like formation presented by blood vessels in the bands in the surrounding tissues of cancer seems to be the characteristic of arteries.
3. As for the direction of flow of arteries in the tissues surrounding cancer, the arteries in the normal case generally run slanting towards the surface of the cervix in the direction of the periphery, but the arteries in

the surrounding tissues of cancer run towards the cancer tissue.

4. Apart from mother blood vessels, the blood vessels in the cancer tissue all present an imperfect capillary-like construction and there is none that possesses the normal arterial or venous construction. Some part is dilatated and other part is narrow, suggesting an imcomplete blood supply. The direction of the flow is also irregular. Mother blood vessels grow rapidly large once they are taken into the cancer tissue.

5. All blood vessels other than the mother vessels reveal an imperfect capillary-like construction in the cancer tissue, and in places the walls of these blood vessels are indistinct; and consequently it is but natural that they bleed so easily.

ACKNOWLEDGEMENT

The author is greatly indebted to Prof. Hideo Yagi and Ass. Prof. Hashimoto for their valuable guidance and painstaking proof reading in preparation of this manuscript.

REFERENCES

1. FUJIWARA, K.: The effect of ligation on the transplantation of mouse sarcoma, *Transacciones Societatis Pathologicae Japonicae*, 10, 141 1920.
2. OSHIMA, F.: Study on transplantable chicken tumor, *Transacciones Societatis Pathologicae Japonicae*, 10, 158, 1920.
3. KOUKETSU, K.: The effect of ligation on the tumor growth, *Transacciones Societatis Pathologicae Japonicae*, 15, 707, 1925.
4. HORIUCHI, M.: The effect of ligation on the transplantation and growth of rabbit sarcoma, *Transacciones Societatis Pathologicae Japonicae*, 15, 709, 1925.
5. KOCHI, S.: Relative growth rates of transplantable tongue tumor according to sites and the effect of severance of tongue arteries on the growth of transplantable tumor, *Kyoto Furitsu Igakkai Zasshi* 6, 31, 1932.
6. GREISCHER, S.: Experimentelle atypische Epithelwucherungen auf dem Boden von Zirkulationsstörungen. *Zeitsch. für Krebsforsch.* 11, 113, 1912.
7. MIDANA, S.: Der Einfluß der aktiven Hyperämie auf das Wachstum der Impftumoren. *Zeitsch. für Krebsforsch.* 31, 28, 1930.
8. HATTORI, J.: Influences of ligation and severance of blood vessels on the growth and proliferation of the tumor transplanted to a different species of animals, *Kumamoto Igakkai Zasshi*, 5, 417, 1929.
9. SUZUE, K. and NAGASE, I.: The relationship between the tumor metastasis and blood vessels, *Kumamoto Igakkai Zasshi*. 6, 685, 1930.
10. SAITO, M.: Arteries of the uterus and organs attached to the uterus, *Kinki-Sanfu-jinka-Zasshi*, 8, 759, 1924.
11. HIRATAKE, C.: The distribution of arteries in cervical carcinoma and uterine myoma, *Aichi Igakkai Zasshi*, 41, 1965, 1934.
12. ITO, K.: Roentgenological study on the arteries of uterine tumor and pregnant uterus, *Aichi Igakkai Zasshi*, 47, 833, 1938.

13. NISHI, T.: The morphology of arteries in normal uterus, uterine myoma, and in the lesions of the endometrium, *Rinsho-Sanfujinka*, 17, 104, 1942.
14. REDLICH, A.: Die Verwendung der X-Strahlen für des Stadium des arteriellen Systems des inneren weiblichen Genitalien. *Arch. f. Anat. u. Physiolog.* 13, 357, 1909.
15. KAWANISHI, G.: The blood vessels of uterine tumor, *Kinki Sanfujinka Zasshi*, 17, 1350, 1934.
16. HYSTL, J.: Die Korsions-anatomie u. ihre Ergebnis. 1873.
17. STELLIO V-Skomnakis.: Blutgefäße bei Carcinoma colli uteri. uteri. *Zeitsch. f. Geburtshilfe u. Gynecologie.* 114, 344, 1937.
18. KREYBERG, L.: Über präcanceröse Gefässveränderungen. *Virch. Arch.* 273, 367, 1929.
19. KREYBERG, L.: Die Rolle der Blutgefäss in d. genese d. Teertumoren. *Zeitsch. für Krebsforsch.* 26, 191, 1928.
20. KREYBERG, L.: On lokal alteration of the blood-vessels of ter-painted white mice. *Brit. Journ. of Exper. Path.* 8, 465, 1927.
21. HINSELMANN, H.: Der Nachweis der aktiven Ausgestaltung der gefäss beim jungen Portiokarzinom als neues differential diagnostisches Hilfsmittel. *Z. bl. f. Gyn.* 64, 1910, 1940.
22. LEWIS, C., SCHEFFEY, BOLTON and LANZ: Colposcopy Acid in diagnosis of cervical Cancer. *Obst. and Gyn.* 3, 5, 1955.
23. IWAZU, T.: Colposcopic examination method. *Rinsho Fujinka Sanka*, 17, 1356, 1934.
24. GOLDMANN: Wandveränderungen an der Gefässen in Bereiche der Neubildung und ihren Umgebung. *Deutsch. med. W. Schrift* 32, 1683, 1906.
25. GOLDMANN: Wandveränderungen an den Gefässen in Bereiche der Neubildung und ihren Umgebung. *Deutsch. med. W. Schrift.* 41, 1683, 1906.
26. GOLDMANN: Die Beziehnngs des Gefässsystem zu dem malignen Neubildungen. *Zeitsch. für Krebsforsch.* 5, 39, 1907.
27. STELLIO V-Skamnakis: Die Blutgefäße bei carcinoma colli uteri. *Zeitsch. bl. f. Gyu.* 61, 1792, 1937.
28. TANAKA, Y.: Blood vessels in malignant tumor. *Gann* 1, 16, 1907.
29. WARREN, H. and Lewis: The vascular patterne of tumors. *Bull of the John Hopkins Hosp.* 41, 156, 1927.
30. SHINOHARA, O.: Observations on the blood vessels in tumors by the reconstruction model. *Gann.* 46, 8, 1955.
31. RIBBERT. H.: Über das Gefässsystem u. die Heilbarkeit der Geschwülste. *Deutsch. med. W. Schrift.* 30, 801, 1904.
32. KUROIWA, T.: Histological study on the early necrosis of cancer cell foci. *Fukuoka Igakkai Zasshi.* 44. 108, 1953.
33. BIERMANN, H.R. KELLY, K.H. and SINGER. G.: Studies of the Blood Supply of tumors in man. *J. of the National Cancer Institute.* 12, 4, 1952.
34. YOSHIDA, T. and KIN, K.K.: The coustruction of the transplanted tumor. *Gann.* 37, 345, 1943.
35. KIN, K.K.: The morphology of blood vessels in the teansplanted tumor. *Nagasaki Medical Journal.* 20, 2177, 1942.
36. MATSUI, H.: The behaviors of the vascular wall against the breast cancer infiltration into tissues, *Journal of the Keio Medical Society* 10, 1085, 1930.
37. MATSUI, H.: The behaviors of the vascular wall against the cancer infiltrstion

- into tissues. *Journal of the Keio Medical Society*. 14, 1221, 1934.
38. KIKUCHI, T.: The behaviors of the blood vessels in malignant tumors, *Transactions Societatis Pathologicae*, 3, 375, 1914.
 39. KIKUCHI, T.: The behaviors of malignant tumor tissue against blood vessels. *Kyoto Furitsu Igakkai Zasshi* 10, 3, 1913.
 40. KIKUCHI, T.: The behaviors of malignant tumor tissue against blood vessels, *The Tokyo Journal of Medical Sciences*. 28, 1, 1914.
 41. TKAI, S.: Morphological study of the endometrium in hemorrhagic diseases, *Okayama Igakkai Zasshi*. 55, 319, 1943.
 42. ITO, M.: The morphological study of the uterine and ovarian tumors, *San-Fujinka-Kiyou*. 20, 315, 1937.
 43. FREUND, R.: Zur Lehre von den Blutgefäßen der normalen und kranken Gebärmütter. 1904.