

Acta Medica Okayama

Volume 35, Issue 5

1981

Article 7

NOVEMBER 1981

Leukocytes in the glomerular capillary lumen in Masugi nephritis. A scanning electron microscopic study of freeze-cracked specimens.

Hirofumi Makino*

Michio Takaoka[†]

Keizo Komoda[‡]

Kiyoyuki Tokuyama**

Zensuke Ota^{††}

Tadashi Ofuji^{‡‡}

Tetsuji Kaneshige[§]

*Okayama University,

[†]Okayama University,

[‡]Okayama University,

**Okayama University,

^{††}Okayama University,

^{‡‡}Okayama University,

[§]Okayama Central Hospital Laboratory,

Leukocytes in the glomerular capillary lumen in Masugi nephritis. A scanning electron microscopic study of freeze-cracked specimens.*

Hirofumi Makino, Michio Takaoka, Keizo Komoda, Kiyoyuki Tokuyama,
Zensuke Ota, Tadashi Ofuji, and Tetsuji Kaneshige

Abstract

Masugi nephritis was induced in rats by a single intravenous injection of rabbit anti-rat kidney serum, and studied with a scanning electron microscope. A characteristic finding was the presence of white cells, probably polymorphonuclear leukocytes, with many microspikes which penetrated through degenerated glomerular endothelial cells to be in direct contact with the glomerular basement membrane. This finding confirms the pathogenic role of leukocytes in glomerulonephritis induced by anti-glomerular basement membrane antibody.

KEYWORDS: Masugi nephritis, scanning electron microscopy, leukocyte.

*PMID: 6459000 [PubMed - indexed for MEDLINE]

Copyright (C) OKAYAMA UNIVERSITY MEDICAL SCHOOL

— BRIEF NOTE —

**LEUKOCYTES IN THE GLOMERULAR CAPILLARY
LUMEN IN MASUGI NEPHRITIS.
A SCANNING ELECTRON MICROSCOPIC STUDY
OF FREEZE-CRACKED SPECIMENS.**

Hirofumi MAKINO, Michio TAKAOKA, Keizo KOMODA,
Kiyoyuki TOKUYAMA, Zensuke OTA, Tadashi OFUJI
and Tetsuji KANESHIGE*

*Third Department of Internal Medicine, Okayama University Medical School,
and *Okayama Central Hospital Laboratory, Okayama 700 Japan*

Received May 27, 1981

Abstract. Masugi nephritis was induced in rats by a single intravenous injection of rabbit anti-rat kidney serum, and studied with a scanning electron microscope. A characteristic finding was the presence of white cells, probably polymorphonuclear leukocytes, with many microspikes which penetrated through degenerated glomerular endothelial cells to be in direct contact with the glomerular basement membrane. This finding confirms the pathogenic role of leukocytes in glomerulonephritis induced by anti-glomerular basement membrane antibody.

Key words : Masugi nephritis, scanning electron microscopy, leukocyte.

Transmission electron microscopy of sectioned samples has confirmed that the heterogenous and autogolous phases of Masugi nephritis are characterized by direct contact of polymorphonuclear leukocytes with the glomerular basement membrane (1-3). This paper describes a scanning electron microscopic study of this behaviour of leukocytes in the nephritis.

Male Sprague-Dawley rats weighing approximately 200g were used. Some animals were injected intravenously with rabbit anti-rat kidney serum, and Masugi nephritis was induced. Others were untreated and used as a control. The nephritic rats were sacrificed 7 days after injection. Under ethyl ether anesthesia, the abdominal cavity of affected and unaffected animals was opened. A polyethylene catheter was cannulated into the abdominal aorta below the renal artery. Maunsbach solution (1 % glutaraldehyde in phosphate buffer pH 7.4) was perfused through the cannulated aorta at a pressure of 100 mmHg. Following this *in situ* fixation, the kidneys were removed, trimmed into appropriate blocks and again fixed, first for 48h with 5 % glutaraldehyde solution, then for an hour with 1 % osmic acid. The specimens were dehydrated through a graded series of ethanol, freeze-fractured in liquid nitrogen, critical-point-dried with liquid CO₂, coated with gold-palladium in a vacuum evaporator (Hitachi HUS-5GB), and ob-

served in a scanning electron microscope (Hitachi HHS-2R) using an accelerating voltage of 25 kV.

Sharply cracked surfaces of the glomeruli were obtained by freeze fracturing. This afforded clear scanning electron microscopic demonstration of the vascular wall. Masugi nephritis was characterized by degeneration of endothelial cells and invasion of white cells, probably polymorphonuclear leukocytes, into the vascular walls (Fig. 1). The degenerated endothelial cells were detached from the glomerular basement membrane. The anchored white cells had many spine-like microspikes which ran beneath the endothelial cells, and the tip of the microspikes being directly attached to the glomerular basement membrane. Detached pieces of endothelial cells were observed in places on the free surface of leukocytes (Fig. 2). Loss and reduction in size and number of endothelial fenestrae, together with unusual development of microvilli, were features of degenerated endothelial cells in Masugi nephritis.

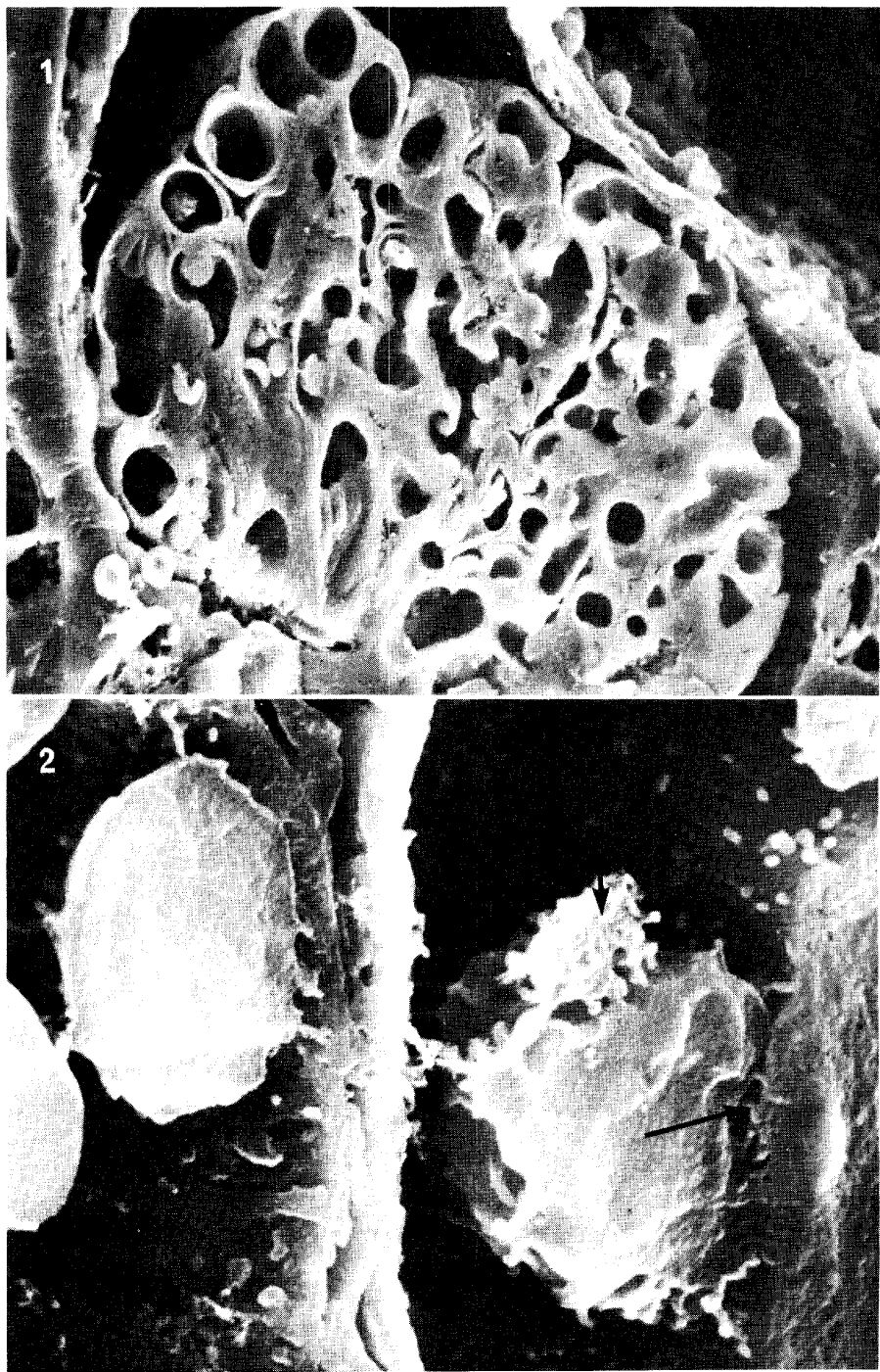
No leukocytes were observed in the glomerular capillary lumen in control or non-treated animals. The glomerular endothelium in these normal animals had numerous regularly shaped fenestrae.

This short communication confirms the previous finding that leukocytes damage the glomerular basement membrane in Masugi nephritis (1-3). It is well known that lysosomal enzymes released from polymorphonuclear leukocytes damage the glomerular basement membrane both *in vivo* (4) and *in vitro* (5-7). The anchoring white cells with typical microspikes observed here seemed to be polymorphonuclear leukocytes. The microspikes of white cells may have some functional significance in the aetiology of damage to glomerular basement membrane.

Acknowledgment. The authors are grateful to Mrs. Sumiko Kikuta and Mr. Juni Aoki for their technical help.

Fig.1. Scanning electron micrographs of a freeze-cracked glomerular surface of rat kidney 7 days after injection of anti-serum. The capillary lumens are widely patent and several leukocytes and red blood cells are seen. $\times 1,100$

Fig. 2. Higher magnification of part of Fig. 1. Note that microspikes of the leukocytes penetrate into the glomerular basement membrane (long arrow). Short arrow indicates a fragment of detached endothelial cell. $\times 11,800$



REFERENCES

1. Albin, B., Brentjens, J.R. and Andres, G.A.: *The Immunopathology of the Kidney*. E. Arnold, London, pp 42-105, 1979.
2. Hawkins, D. and Cochrane, C.G.: Glomerular basement membrane damage in immunological glomerulonephritis. *Immunology* **14**, 665-681, 1968.
3. Cochrane, C.G., Unaue, E.R. and Dixon, F.J.: A role of polymorphonuclear leukocytes and complement in nephrotoxic nephritis. *J. Exp. Med.* **122**, 99-116, 1965.
4. Henson, P.M.: Interaction of cells with immune complexes: adherence release of constituents and tissue injury. *J. Exp. Med.* **134**, 114s-135s, 1971.
5. Cochrane, C.G. and Aikin, B.S.: Polymorphonuclear leukocytes in immunologic reactions. *J. Exp. Med.* **124**, 733-755, 1966.
6. Janoff, A. and Zelig, J.D.: Vascular injury and lysis of basement membrane *in vitro* by neutral protease of human leukocytes. *Science* **161**, 702-704, 1968.
7. Makino, H., Ota, Z., Takaya, Y., Miyoshi, A. and Ofuji, T.: Morphological changes of the molecular sieve in bovine glomerular basement membrane by protease and lysosomal enzyme digestion. *J. Electron Microsc.* **29**, 242-249, 1980.