



# Combining pullout suture and retrograde screw fixation for anterior cruciate ligament tibial eminence avulsion fractures: A case report

Journal of Orthopaedic Surgery  
28(2) 1–5

© The Author(s) 2020

Article reuse guidelines:  
sagepub.com/journals-permissions  
DOI: 10.1177/2309499020918681  
journals.sagepub.com/home/osj



Takaaki Hiranaka<sup>1</sup> , Takayuki Furumatsu<sup>1</sup>, Takaaki Tanaka<sup>2</sup>,  
Yuki Okazaki<sup>1</sup> , Yuya Kodama<sup>1</sup>, Yusuke Kamatsuki<sup>1</sup>,  
Kenji Masuda<sup>2</sup>, Noritaka Seno<sup>2</sup> and Toshifumi Ozaki<sup>1</sup>

## Abstract

This report describes a novel arthroscopic technique for the treatment of anterior cruciate ligament (ACL) tibial eminence avulsion fractures. A 16-year-old boy who was diagnosed with a left ACL tibial eminence avulsion fracture was treated by arthroscopic fixation. Two bone tunnels were created from the anterior tibial cortex into the fracture bed, and a strong suture passed through the ACL just above its insertion was pulled out through them for reduction and fixation. A retrograde cannulated screw fixation was added for stronger fixation. Weight-bearing and range of motion exercises were started immediately after surgery. Radiographically, bone union was obtained 6 months postoperatively. During second-look arthroscopy (24 months postoperatively), there was no loss of reduction and no subsequent meniscal or cartilage injuries. At that point, the Lysholm score was 95, and the International Knee Documentation Committee score was 96.

## Keywords

anterior cruciate ligament, knee, pullout suture, screw fixation, tibial eminence avulsion fracture

Date received: 30 December 2019; Received revised 20 March 2020; accepted: 22 March 2020

## Introduction

Anterior cruciate ligament (ACL) tibial eminence avulsion fractures most commonly occur in children and adolescents<sup>1</sup> and are equivalent to a torn ACL in adults.<sup>2</sup> Meyers and McKeever classified these fractures into four types, which is useful for decision-making in diagnosis and treatment.<sup>3,4</sup> The un-displaced fractures (type I) are often treated conservatively, while the displaced fractures (type II, if a reduction is not anatomical, and type III and IV fractures) are often operated. When operations are utilized, various techniques including cannulated screws,<sup>5</sup> Kirschner wires,<sup>6</sup> steel wires,<sup>7</sup> staples, and intraosseous sutures<sup>8,9</sup> have been reported in past literature. Recently, screws and suture fixation have become well established and commonly used surgical techniques; good knee stability and favorable clinical results have been reported using these

techniques. However, complications such as nonunion, residual instability associated with loss of fracture reduction, or articular stiffness with longer immobilization after surgery have been reported in some cases. The use of stronger internal fixation may reduce the possibility of loss of fracture reduction and allow for more aggressive rehabilitation to help prevent articular stiffness.<sup>10</sup> This report

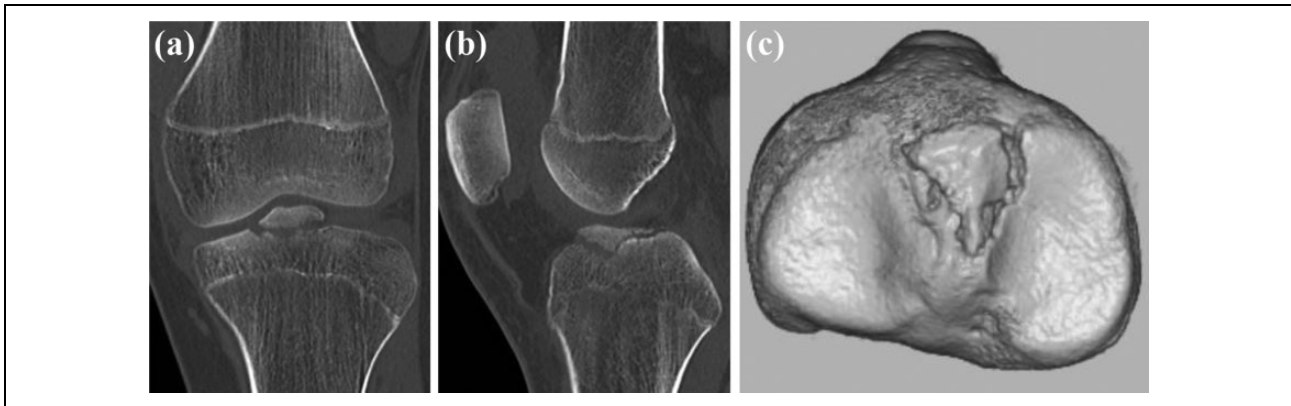
<sup>1</sup> Department of Orthopaedic Surgery, Okayama University Hospital, Okayama, Japan

<sup>2</sup> Department of Orthopaedic Surgery, Sumitomo Besshi Hospital, Ehime, Japan

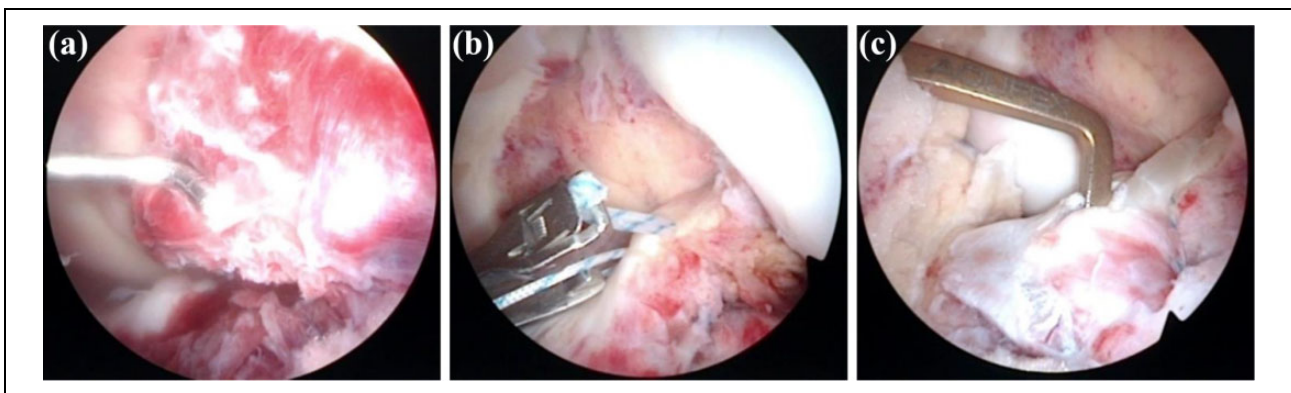
### Corresponding author:

Takayuki Furumatsu, Department of Orthopaedic Surgery, Okayama University Hospital, 2-5-1 Shikatacho, Kitaku, Okayama 700-8558, Japan.  
Email: matino@md.okayama-u.ac.jp





**Figure 1.** Preoperative CT images of the left knee showing a Meyers and McKeever type III ACL tibial eminence avulsion fracture. (a) Coronal view, (b) sagittal view, and (c) three-dimensional CT image. ACL: anterior cruciate ligament; CT: computed tomography.



**Figure 2.** Arthroscopic findings during surgery. (a) The avulsed fragment at the anterior tibial eminence was dislocated upward. (b) A suture passer with a strong suture was passed through, just above the ACL insertion to the fragment for reduction and fixation. (c) A cannulated screw whose thread length was shortened was inserted to the fragment for stronger fixation. ACL: anterior cruciate ligament.

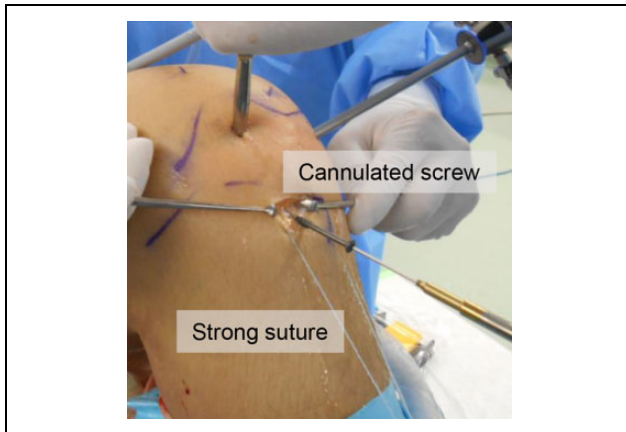
describes a 16-year-old boy who experienced a left ACL tibial eminence avulsion fracture and was treated by combination pullout sutures with retrograde screws for stronger fixation.

## Case presentation

This study received the approval of our Institutional Review Board, and the patient gave his informed consent for this case report. A 16-year-old boy fell during walking on the street in a traffic accident. In the physical examination, the range of motion (ROM) of his left knee was determined to be restricted to 10°–90° due to knee swelling, and Lachman and pivot shift tests were both positive. Plain radiography and computed tomography (CT) showed the avulsed fragment at the ACL attachment site of the left tibia to be completely displaced from the tibia (Figure 1). Magnetic resonance imaging showed that the ACL fibers were not ruptured. The patient was diagnosed with a Meyers and McKeever type III ACL avulsion fracture of the left anterior tibial eminence. Arthroscopy showed that

the avulsed fragment at the anterior tibial eminence was dislocated upward [Figure 2(a)]. There were no findings suggesting ACL parenchyma injury or rupture.

The patient was placed in the supine position with a tourniquet. Standard anterolateral and anteromedial portals were used. The ACL was probed to ensure that the femoral attachment was intact, and there was no intraligamentous tear. A suture passer with a strong suture was inserted through just above the ACL insertion to the fragment [Figure 2(b)]. Two bone tunnels were created in a retrograde manner from the anterior tibial cortex into the fracture bed using a 2.4-mm guide pin with an ACL drill guide system. The suture passed through the ACL was pulled out through these tunnels for anatomical reduction of the fragment [Figure 2(b)]. After reduction of the fragment, the screw fixation was performed using a cannulated cancellous screw. A 1.5-mm guide pin was drilled from the medial tibial tubercle to the bone fragment using an ACL guide. A cannulated cancellous screw 4.0 mm in diameter, 42 mm in total length, and 16 mm in thread length was used. For preventing the screw tip protrusion into the articular joint,



**Figure 3.** A retrograde cannulated screw whose thread length had been already shortened was inserted to the fragment.

causing cartilage damage or impingement, the distal part of the screw thread was cut, and the thread length was shortened to 5 mm, as the depth of the bone fragment was 5.5 mm on the sagittal view of the CT images [Figures 2(c) and 3]. When the screw or guide pin was inserted into the avulsed fragment, the suture was pulled out and tensioned; thus, the fragment was firmly attached to the bone bed, and it was easily inserted. After cannulated screw fixation, the pulled-out suture was fixed by a cortical fixation device over the tibial cortex. The ROM exercises were allowed immediately after surgery, and weight-bearing was allowed after achieving straight leg raising. In this case, the straight leg raising was achieved on the first day after surgery, and weight-bearing was allowed from that day onwards. No restriction was imposed on ROM and weight-bearing. For the prevention of the injury caused by muscle weakness, a crutch was used for 2 weeks.

Six months postoperatively, radiological imaging determined no loss of reduction; the bone union was obtained on X-ray and CT images. [Figure 4(a) and (b)]. Fortunately, we were provided the opportunity to perform second-look arthroscopy 24 months after the primary surgery as the patient wanted the implant removed for religious reasons. During arthroscopy, a tensioned ACL and no lifting of a fragment were both confirmed [Figure 4(c)]. There was no subsequent meniscal injury or severe chondral damage. The ROM of his left knee was  $0^{\circ}$ – $150^{\circ}$ , and both the Lachman test and pivot shift test were negative. Visual analog scale was 0, mean Tegner score was 5, the Lysholm score was 95 points, and the International Knee Documentation Committee score was 96. Radiological imaging determined no loss of reduction; the bone union was obtained on X-ray and CT images.

## Discussion

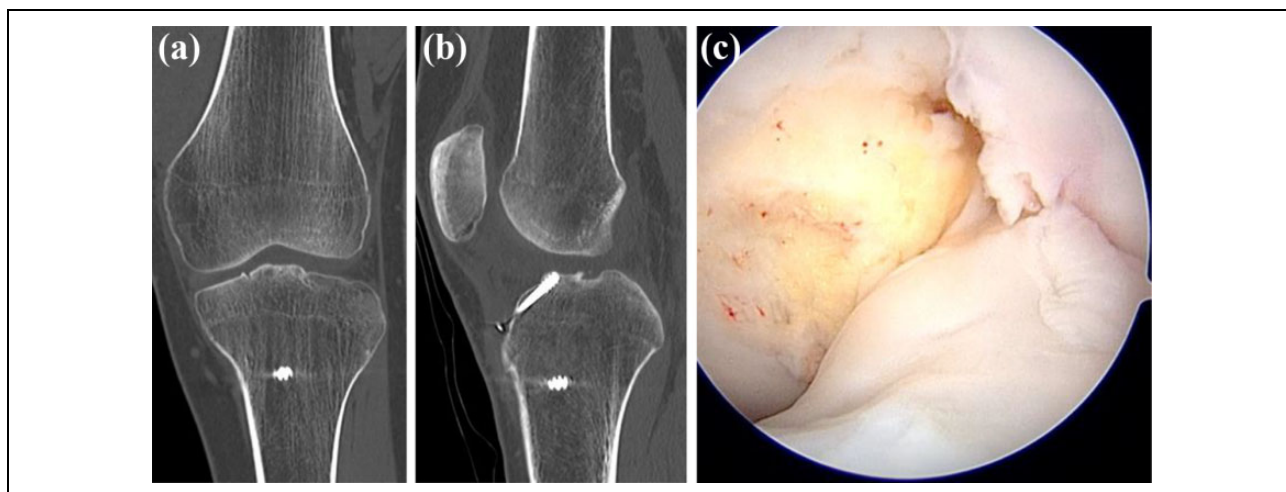
The fixation technique employed is crucial to the success of the fixation of ACL tibial eminence avulsion fractures.

Various arthroscopic fixation techniques have been reported for tibial eminence avulsion fractures, and fixations with screws and sutures are the most common methods at present. Osti et al. reviewed the past literature and reported both methods to have obtained satisfactory results.<sup>11</sup>

Screw fixation has the advantage of direct reduction and compression of the fracture fragment and allows for relatively early mobilization.<sup>11</sup> In contrast, if the antegrade screw is positioned, there are risks of screw head impingement on the intercondylar notch or knee cartilage damage, requiring implant removal after the bone union.<sup>12</sup> Therefore, this case used a retrograde screw whose thread was partially cut, shortened, and positioned so that the screw tip could not protrude into the articular joint and cause chondral damage or impingement. In this case, the fracture was Meyers and McKeever type III with relatively large bone fragment; thus, screw fixation was added to the pullout suture fixation. If the fracture type was Meyers and McKeever type IV (commuted) or Meyers and McKeever type II or III with small fragment less than 5 mm, it would be technically difficult to perform the retrograde screw fixation from our case. Therefore, though the utility of this fixation technique might be limited, the retrograde screw fixation should be performed when the size of the bone fragment is more than 5 mm.

On the other hand, previous research has determined that suture fixation strength was superior to single screw fixation strength in biomechanical testing.<sup>13,14</sup> Bong et al. reported that the initial ultimate strength of FiberWire fixation was significantly stronger than that of cannulated screw fixation using cadaveric specimens (319 N vs. 129 N).<sup>13</sup> Additionally, Li et al. reported that traditional suture fixation had a higher ultimate failure load than screw fixation (384 N vs. 195 N).<sup>14</sup> To obtain firmer stability, we used both the pullout suture technique and cannulated screw fixation. In some literature, residual laxity was reported as one of the main complications of the treatment of an eminence fracture.<sup>15,16</sup> Therefore, stronger fixation using a combination of two fixation techniques would secure postoperative knee stability and allow early mobilization and weight-bearing. Past reports using pullout suture fixation demonstrated that a long leg splint was applied for 1–2 weeks, and a full ROM exercise was allowed 8 weeks postoperatively; full weight-bearing was performed 3 months postoperatively after confirmation of bone union.<sup>8,17</sup> Early mobilization has been shown to decrease the risk of arthrofibrosis and loss of knee motion, improve clinical outcomes, and allow an earlier return to daily activities.<sup>18,19</sup> In this case, the mobilization and weight-bearing were started shortly after surgery, earlier than in the past literature, and a favorable clinical outcome and knee stability were obtained.

We usually perform screw removal during the second-look arthroscopy. Most Japanese want the metal removal for religious reasons, and we usually perform tibial metal



**Figure 4.** Postoperative CT images of left knee showed bone union in (a) Coronal view and (b) sagittal view (6 months postoperatively). (c) During second-look arthroscopy, ACL was tensioned and no findings of a fragment lifting by probing were observed. ACL: anterior cruciate ligament; CT: computed tomography.

removal about 1 year postoperatively after confirmation of bone union. At the same time, we also perform second-look arthroscopy.<sup>20–22</sup> It is useful not only to confirm the bone union and evaluate the quality of ACL but also to check the presence of post-traumatic meniscal injury or chondral damage and perform additional procedures if the lesions need to be treated.

## Conclusion

An ACL tibial eminence avulsion fracture was treated by a combination of two fixation techniques - pullout suture and retrograde screw. This novel treatment could be applied to the relatively large tibial eminence fragment and allowed early mobilization, hence obtaining radiographic and clinical outcomes that prove favorable.

## Acknowledgment

The authors would like to thank Editage (<http://www.editage.jp>) for English language editing.



## Declaration of conflicting interests

The author(s) declared no potential conflicts of interest with respect to the research, authorship, and/or publication of this article.

## Funding

The author(s) received no financial support for the research, authorship, and/or publication of this article.

## ORCID iD

Takaaki Hiranaka  <https://orcid.org/0000-0001-8671-8256>  
Yuki Okazaki  <https://orcid.org/0000-0002-6591-5100>

## References

- Andersen JW and Mejdahl S. Bilateral fracture of the tibial spine. *Acta Orthop Belg* 1993; 59: 394–397.
- Lubowitz JH and Grauer JD. Arthroscopic treatment of anterior cruciate ligament avulsion. *Clin Orthop Relat Res* 1993; 242–246.
- Meyers MH and McKeever FM. Fracture of the intercondylar eminence of the tibia. *J Bone Joint Surg Am* 1959; 41-A: 209–220; discussion 220–202.
- Meyers MH and McKeever FM. Fracture of the intercondylar eminence of the tibia. *J Bone Joint Surg Am* 1970; 52: 1677–1684.
- Choi NH and Kim SJ. Arthroscopic reduction and fixation of bony avulsion of the posterior cruciate ligament of the tibia. *Arthroscopy* 1997; 13: 759–762.
- McLennan JG. The role of arthroscopic surgery in the treatment of fractures of the intercondylar eminence of the tibia. *J Bone Joint Surg Br* 1982; 64: 477–480.
- Calpur OU, Copuroglu C, and Ozcan M. Avulsion fractures of both anterior and posterior cruciate ligament tibial insertions. *Knee Surg Sports Traumatol Arthrosc* 2002; 10: 223–225.
- Ahn JH and Yoo JC. Clinical outcome of arthroscopic reduction and suture for displaced acute and chronic tibial spine fractures. *Knee Surg Sports Traumatol Arthrosc* 2005; 13: 116–121.
- Vargas B, Lutz N, Dutoit M, et al. Nonunion after fracture of the anterior tibial spine: case report and review of the literature. *J Pediatr Orthop B* 2009; 18: 90–92.
- Vander Have KL, Ganley TJ, Kocher MS, et al. Arthrofibrosis after surgical fixation of tibial eminence fractures in children and adolescents. *Am J Sports Med* 2010; 38: 298–301.
- Osti L, Buda M, Soldati F, et al. Arthroscopic treatment of tibial eminence fracture: a systematic review of different fixation methods. *Br Med Bull* 2016; 118: 73–90.
- Senekovic V and Veselko M. Anterograde arthroscopic fixation of avulsion fractures of the tibial eminence with a

- cannulated screw: five-year results. *Arthroscopy* 2003; 19: 54–61.
13. Bong MR, Romero A, Kubiak E, et al. Suture versus screw fixation of displaced tibial eminence fractures: a biomechanical comparison. *Arthroscopy* 2005; 21: 1172–1176.
  14. Li J, Yu Y, Liu C, et al. Arthroscopic fixation of tibial eminence fractures: a biomechanical comparative study of screw, suture, and suture anchor. *Arthroscopy* 2018; 34: 1608–1616.
  15. Jackson TJ, Storey EP, Ganley TJ, et al. The surgical management of tibial spine fractures in children: a survey of the pediatric orthopaedic society of North America (POSNA). *J Pediatr Orthop* 2017. DOI: 10.1097/BPO.0000000000001073.
  16. Tudisco C, Giovarruscio R, Febo A, et al. Intercondylar eminence avulsion fracture in children: long-term follow-up of 14 cases at the end of skeletal growth. *J Pediatr Orthop B* 2010; 19: 403–408.
  17. Huang TW, Hsu KY, Cheng CY, et al. Arthroscopic suture fixation of tibial eminence avulsion fractures. *Arthroscopy* 2008; 24: 1232–1238.
  18. Patel NM, Park MJ, Sampson NR, et al. Tibial eminence fractures in children: earlier posttreatment mobilization results in improved outcomes. *J Pediatr Orthop* 2012; 32: 139–144.
  19. Montgomery KD, Cavanaugh J, Cohen S, et al. Motion complications after arthroscopic repair of anterior cruciate ligament avulsion fractures in the adult. *Arthroscopy* 2002; 18: 171–176.
  20. Hiranaka T, Furumatsu T, Kamatsuki Y, et al. Posttraumatic cartilage degradation progresses following anterior cruciate ligament reconstruction: a second-look arthroscopic evaluation. *J Orthop Sci* 2019; 24(6): 1058–1063.
  21. Hiranaka T, Furumatsu T, Kamatsuki Y, et al. Early chondral damage following meniscus repairs with anterior cruciate ligament reconstruction. *Asia Pac J Sports Med Arthrosc Rehabil Technol* 2020; 20: 1–5.
  22. Hiranaka T, Furumatsu T, Okazaki Y, et al. Bilateral anterior cruciate ligament tear combined with medial meniscus posterior root tear. *Acta Med Okayama* 2019; 73: 523–528.