

Biomechanical Comparison of Posterior Fixation Using Spinal Instrumentation and Conventional Posterior Plate Fixation in Unstable Vertical Sacral Fracture

Kensuke Shinohara^a, Tomoyuki Takigawa^a, Masato Tanaka^{a*}, Yoshihisa Sugimoto^a,
Shinya Arataki^a, Yasuo Ito^b, and Toshifumi Ozaki^a

^aDepartment of Orthopaedic Surgery, Okayama University Graduate School of Medicine, Dentistry and Pharmaceutical Sciences, Okayama 700-8558, Japan, and ^bDepartment of Orthopaedic Surgery, Japanese Red Cross Kobe Hospital, Kobe 651-0073, Japan

Vertical sacral fracture is one of the most difficult fractures to treat. Posterior fixation using spinal dual rods is a novel method for treating this fracture, but its biomechanical strength has not yet been reported. The aim of this study was to evaluate the biomechanical strength produced by posterior fixation using spinal instrumentation. Sacral fractures were created in eight pelvic bone models and classified into a posterior plate fixation group [P group, $n = 4$] and a spinal instrumentation group [R group, $n = 4$]. The biomechanical strength was tested by pushing down on the S1 vertebra from the top. The mean maximum loads were 1,057.4 N and 1,489.4 N in the P and R groups, respectively ($p = 0.014$). The loads applied to the construct at displacements of 5 mm and 7.5 mm from the start of the universal testing machine loading were also significantly higher in the R group. The mean stiffness levels in the P and R groups were 88.3 N/mm and 119.6 N/mm, respectively ($p = 0.014$). Posterior fixation using spinal instrumentation is biomechanically stronger than conventional posterior plate fixation. This procedure may be the optimal method for treating unstable sacral fracture fixation.

Key words: biomechanical comparison, sacral fracture, posterior fixation, spinal instrumentation

An unstable sacral fracture is a severe condition caused by high-energy trauma that can negatively impact life expectancy. Unstable sacral fractures are reported to result from multiple causes, including motorcycle crashes, automobile-pedestrian collisions, motor vehicle crashes, and falls [1]. Most of these occurrences involve multiple traumas, which increase the risk of massive hemorrhaging of the thoracic cavity, abdominal cavity, soft tissue, pelvis, and limbs. Initial treatment requires general management,

hemorrhage assessment, and hemostasis, with early treatment an essential step towards achieving a good prognosis and preventing future dysfunction. However, surgical fixation can be challenging for trauma surgeons [2], with the reduction and fixation of sacral fractures reported to be particularly difficult [3].

There are several methods of posterior pelvic fixation, with numerous reports comparing the biomechanics of posterior plates, transiliac bars, iliosacral screws, lumbosacral fixation, and external fixation [4–10], while others have described fixation using

Received July 7, 2015; accepted November 17, 2015.

*Corresponding author. Phone: +81-86-223-7151; Fax: +81-86-235-7636
E-mail: tanakam@md.okayama-u.ac.jp (M. Tanaka)

Conflict of Interest Disclosures: No potential conflict of interest relevant to this article was reported.

spinal implants [6, 7, 10–14]. However, there are currently no published studies reporting a biomechanical comparison of posterior fixation using spinal instrumentation vs. conventional posterior plate fixation. In the present study, an iliac screw was used for fixation and a dual rod construct was used for spinal instrumentation. The aim of the present study was to compare and evaluate the biomechanical strength produced by posterior fixation using spinal instrumentation vs. that produced using conventional posterior plate fixation.

Subjects and Methods

Bone model preparation and surgical techniques. Unilateral, Denis zone 2 sacral fractures were created using a bone saw. A total of eight artificial pelvic bone male models (SAWBONES; Vashlon, WA, USA) were divided into 2 study groups: a posterior plate group [plate (P) group, $n = 4$] and a spinal instrument group [rod (R) group, $n = 4$]. The P group construct was created according to the surgical procedure reported by Kobbe *et al.* [15]. First, an adequate amount of posterior superior iliac spine was resected at the plate placement site. Next, a 10-hole, 4.5-mm locking compression plate (Depuy Synthes; West Chester, PA, USA) was adjusted by bending it to align with the sacral and iliac bone surface. Thereafter, 4.5-mm cortical screws were inserted to fix the plate and bilateral ilium (Fig. 1A).

Two screws with a length of 64mm were inserted towards the anterior inferior iliac crest, and 4 screws with a length of 20mm were inserted at the iliac wing.

In the R group, 2 polyaxial screws (Depuy Synthes; Raynham, MA, USA) were inserted into the ilium. An iliac bone block 2cm in length and 1cm in depth was resected from the posterior superior iliac crest as a screw insertion site. The insertion trajectory was towards the anterior inferior iliac spine, as previously described by Santos *et al.* [16]. Two screws with a diameter of 7.0mm were inserted into both sides, with a proximal screw length of 45mm and a distal screw length of 65mm. Thereafter, 2 cross-linking rods with a diameter of 5.5mm were secured to the polyaxial screw head (Fig. 1B). All test models were prepared by the same orthopedic surgeon.

Biomechanical testing. Computed tomography (CT) scans of the pelvic models were obtained

before testing to ensure that the model could be accurately installed in the universal testing machine (Instron, Canton, MA, USA). A custom fixation jig was then created (Fig. 2) on a three-dimensional (3D) printer (Stratasys, Rehovot, Israel) using acrylic resin.




Fig. 1 A, Conventional posterior plate fixation; B, The posterior fixation using spinal instrumentation. Arrows: Transforaminal fracture line.

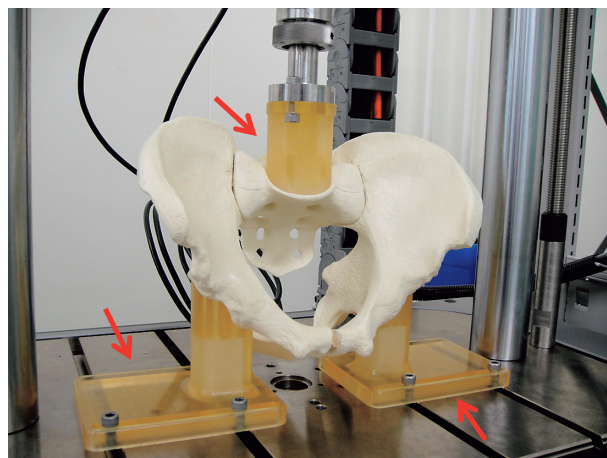


Fig. 2 Biomechanical testing device and pelvic fixation jig. Arrows: The pelvic fixation jig was made of acrylic resin created by a 3D printer to perfectly suit the sacral inclination and bilateral acetabulum. The axial load was applied from the top.

The bone models were placed at an angle of 40° on the universal testing machine with the fixation jig. The sacral inclination angle for each pelvic model was based on the mean value calculated by Vailla *et al.* [17] using the pelvic radiographs of 300 asymptomatic volunteers. An axial load was applied from the top in order to push down the sacrum. The loading speed was set at 10 mm/min. In each test model, the starting point of displacement (in mm) was defined and set when an applied load of 5 N became stable. The axial load was applied until the load reached its maximum. The displacement and load data were collected at 100 Hz. The maximum load was measured and, the load data were extracted at displacements of 5 mm and 7.5 mm beginning at the start of the universal testing machine loading. The mean pelvic stiffness (N/mm) was also measured. A scatter diagram of the load and displacement was prepared, and the linear approximation was calculated using the least-squares method. Stiffness was defined as the slope of the linear approximation from 0 mm to 5 mm in displacement. The scatter diagram displacement ranged from 0 mm to 5 mm based on a report on the long-term follow-up of pelvic ring fractures which found that a mean posterior displacement of 5.2 mm is unstable [18].

Statistical analyses were performed using StatMate V for Win & Mac Hybrid (3B Scientific Inc.; Hamburg, Germany). The results are presented as the mean \pm SD. Significant differences between the 2 test groups were measured using the Mann-Whitney U test, with a p -value of < 0.05 considered to be significant.

Results

The mean maximum loads for the P and R groups were $1,057.4 \pm 244.9$ N and $1,489.4 \pm 34.7$ N, respectively ($p = 0.014$) (Fig. 3). The mean load bearings for the P and R groups at a displacement of 5 mm were 438.3 ± 57.3 N and 590.3 ± 40.4 N ($p = 0.014$), respectively, and at a displacement of 7.5 mm they were 744.5 ± 102.1 N and 893.3 ± 53.3 N ($p = 0.014$), respectively (Fig. 4, 5). The group results were significantly different for both displacements. The mean stiffness was 88.3 ± 13.9 N/mm in the P group and 119.6 ± 6.7 N/mm in the R group, which also constitutes a significant difference ($p = 0.014$) (Fig. 6). For all evaluated parameters, the R group showed significantly

higher values than the P group. Neither group developed an implant fracture. However, all models that started to distract at the sacral fracture site showed an iliac wing fracture on the right side or displacement of the sacroiliac joint on the left side after biomechanical testing.

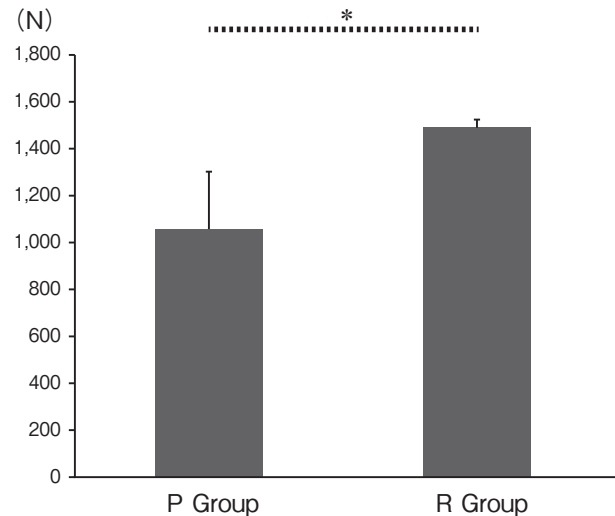


Fig. 3 The mean maximum load. The mean maximum was significantly higher in the R group. P group: Conventional posterior plate fixation. R group: Posterior fixation using spinal instrumentation. *: p -value < 0.05

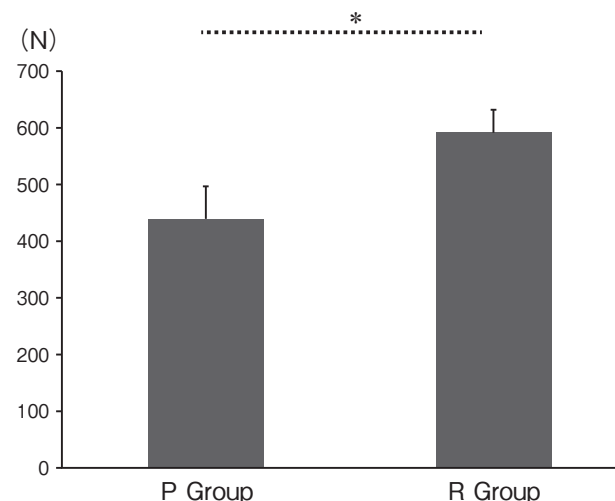


Fig. 4 The mean load at a 5.0-mm displacement. The load of the 5.0-mm displacement was higher in the R group. P group: Conventional posterior plate fixation. R group: Posterior fixation using spinal instrumentation. *: p -value < 0.05

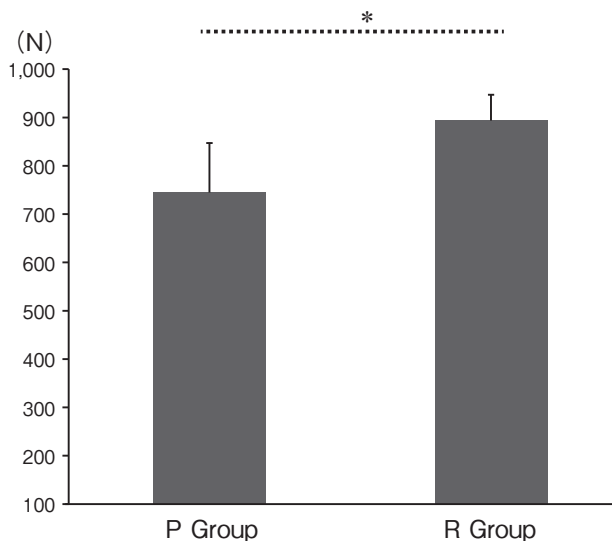


Fig. 5 The mean load at a 7.5-mm displacement. The load of the 7.5-mm displacement was higher in the R group. P group: Conventional posterior plate fixation. R group: Posterior fixation using spinal instrumentation. *: p -value < 0.05

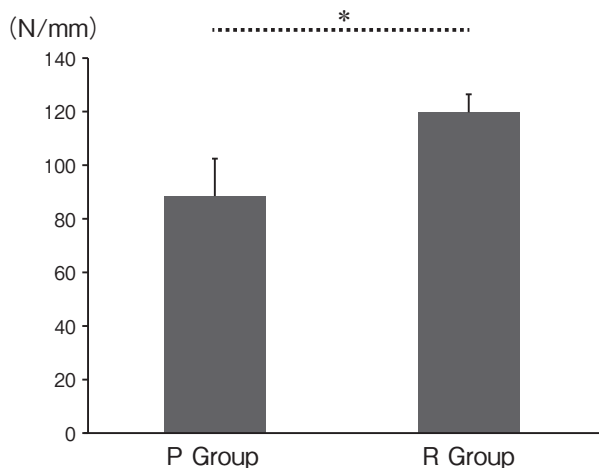


Fig. 6 The mean stiffness. The mean stiffness was significantly higher in the R group. P group: Conventional posterior plate fixation. R group: Posterior fixation using spinal instrumentation. *: p -value < 0.05

Discussion

Unstable pelvic ring fractures, including sacral fractures, are caused by multiple traumas resulting from a high-energy injury. Some potential consequences of this injury, such as massive hemorrhaging in the pelvis, can be fatal. Nerve injury caused by a sacral fracture is correlated with subsequent dysfunction [17]; therefore, early diagnosis and suitable treatment are important. While curative treatment is required for the patient to achieve rehabilitation and return to everyday life activities, such treatment is challenging. Although a wide range of treatments are available, no consensus has been reached regarding the approach that is most likely to produce favorable outcomes.

The aim of the present study was to examine the biomechanical strength of posterior fixation achieved using spinal instrumentation compared with that achieved using conventional posterior plate fixation to determine the effectiveness of spinal instrumentation fixation in treating surgically curable sacral fractures. Various methods, such as those using a plate, spinal instrumentation, or iliosacral screw, have been devised and biomechanically tested [4–14]. In posterior plate fixation, it is believed that the plate can be incompatible with some individuals depending on differences in pelvic size and shape. Furthermore, the procedure is considerably more invasive. Therefore, as a curative treatment for unstable sacral fractures, we propose the use of spinal instrumentation in surgical fixation based on its high degree of flexibility and ease of placement. To date, several reports have described the fixation of unstable pelvic fractures using spinal instrumentation [6, 7, 10–14]. Schildhauer *et al.* [6] biomechanically compared lumbosacral fixation using spinal instrumentation to the use of iliosacral screws in human cadavers and reported that lumbosacral fixation was clearly superior. Berber *et al.* [12] created Denis type 2 sacral fractures in a pelvic bone model and compared bilateral iliosacral screws, tension band plates, combined bilateral iliosacral screws and their own devised pelvic reconstruction system using spinal instrumentation. Among these various approaches, their pelvic reconstruction system was the most stable construct. In another study, Toogood *et al.* [13] created a pelvic bone model of left sacral fractures and biomechanically compared constructs fixed with a rod and iliac screws inserted into the left ilium utilizing either ipsilateral S1 pedicle screws or contralateral S1 pedicle screws. The displacement was not significantly different between these 2 constructs. Another fixation method using an S1 pedicle screw and iliac screws connected by rod-screw connectors was an effective substitute for maintaining the repositioned site [11]. Furthermore, Vigdorchik *et al.* [10]

developed a supra-acetabular pedicle screw internal fixation device using spinal instrumentation. As demonstrated by these multiple reports, the use of spinal instrumentation has become a standard technique for the anterior and posterior fixations used in clinical practice to treat pelvic fractures.

Although Abdelfattah *et al.* [3] reported the treatment of clinical cases of pelvic fracture with dual rods and four iliac screws as being rapid, easy, safe, and minimally invasive, no biomechanical comparison of dual rod fixation using spinal instrumentation and conventional posterior plate fixation has been reported. Our study demonstrated that the construct using spinal instrumentation was significantly stiffer than posterior plate fixation. Furthermore, the maximum load and the load applied to the construct at 5mm and 7.5mm from the start were significantly higher in the spinal instrumentation group. Spinal instrumentation methods have the advantage that both long and thick-diameter screws and crosslinking dual rods are readily available. Lynn *et al.* reported that both the rotational stiffness and the lateral bending stiffness of a two-crosslink construct in the spine were significantly higher than those of a zero-crosslink system [19]. These results correlate with our findings and show that crosslink placement makes the construct stiffer in the direction vertical to the rod. We believe that applying the crosslink connector to the dual rods provided the construct with strong vertical resistance to the axial pressure.

Spinal instrumentation achieves high flexibility because the rod length is adjustable and the screw head is flexible. Fracture reduction is simple and easy for a surgeon because the inserted screws can be used as joysticks with which to apply a reduction force. Conversely, reduction maneuverability is minimal with the posterior plate, which often results in *in situ* fixation. Massive exposure of the ilium, the sacrum and the location of the fracture is required to fit the posterior plate to the sacrum. From this viewpoint, rod insertion under the muscular layer is less invasive than plate attachment.

One disadvantage of dual rod fixation is that, it requires resection of the iliac bone. However, resecting the iliac bone can prevent wound infection and can also minimize the localized pain caused by the screw head. This resected bone is also useful for bone grafting.

The present study has some limitations. Firstly, we performed our investigations using artificial pelvic bone models, whereas most reports describe biomechanical tests using human cadaver specimens [6–9]. However, artificial pelvic bone models have the advantage of all being made with identical material and being identical in shape, thereby eliminating variability and facilitating the creation of a bone fracture model. Several biomechanical studies have used artificial bone models and elicited good data [4, 10, 13]. Furthermore, we used CT data from artificial pelvic bone models to create dedicated fixation jigs on a 3D printer, which enabled us to standardize the placement in the universal testing machine for all experiments. The jig was completely adapted to the sacral inclination and bilateral acetabulum, which we believe improved the reliability of our biomechanical tests. One disadvantage of using an artificial pelvic bone model is that the support provided by ligaments and muscular tissue cannot be taken into consideration during loading [5, 11]. Secondly, an axial load was selected for the current biomechanical testing because unstable sacral fractures are generally caused by a vertical shearing force. Furthermore, the present study tested static mechanical strength; however, no comparison was performed under cyclic loading. Although only one force direction was tested in this study, our results should be clinically relevant. Finally, we only tested and compared two methods of repair. Biomechanical tests of various surgical fixation methods should be performed under standardized conditions.

In conclusion, when treating unstable sacral fractures, early intervention is crucial in order to obtain a good prognosis and functional recovery. Surgery for patients with multiple traumas should be minimally invasive and should be completed in a short time period. Posterior fixation using spinal instrumentation is a technique that fulfills all of these criteria. In addition, there is a minimal risk of iatrogenic complications. This study shows that posterior fixation using spinal instrumentation is biomechanically stronger than conventional posterior plate fixation. We believe that this technique is an effective surgical procedure.

Acknowledgments. They have no relevant financial activities outside of the submitted academic affiliations.

References

1. Durkin A, Sagi C, Durham R and Flint L: Contemporary management of pelvic fractures. *Am J Surg* (2006) 192: 211–223.
2. Falah M, Rozen N, Chezar A, Hannani A and Soudry M: Fixation of posterior pelvic disruption by trans-iliac bar ISOLA rods and hooks. *Injury Extra* (2005) 36: 376–379.
3. Abdelfatta MF, Saoud M and Abdelwahab R: The Internal fixator: a novel technique for stabilization of transforaminal sacral fractures as a part of pelvic ring disruption. a preliminary report. *WSCJ* (2011) 2: 27–36.
4. Yinger K, Scalise J, Olson SA, Bay BK and Finkemeier CG: Biomechanical comparison of posterior pelvic ring fixation. *J Orthop Trauma* (2003) 17: 481–487.
5. Sahin O, Demirors H, Can Akgun R and Tuncay IC: Internal fixation of bilateral sacroiliac dislocation with transiliac locked plate: a biomechanical study on pelvic models. *Acta Orthop Traumatol Turc* (2013) 47: 411–416.
6. Schildhauer TA, Ledoux WR, Chapman JR, Henley MB, Tencer AF and Chip Routt ML: Triangular osteosynthesis and iliosacral screw fixation for unstable sacral fractures: a cadaveric and biomechanical evaluation under cyclic loads. *J Orthop Trauma* (2003) 17: 22–31.
7. Dawei T, Na L, Jun L, Wei J and Lin C: A novel fixation system for sacroiliac dislocation fracture: internal fixation system design and biomechanics analysis. *Clin Biomech* (2013) 28: 129–133.
8. Mears SC, Sutter EG, Wall SJ, Rose DM and Belkoff SM: Biomechanical comparison of three methods of sacral fracture fixation in osteoporotic bone. *Spine* (2010) 35: 392–395.
9. Humphrey CA, Liu Q, Templeman DC and Ellis TJ: Locked plates reduce displacement of vertically unstable pelvic fractures in a mechanical testing model. *J Trauma* (2010) 69: 1230–1234.
10. Vigdorichik JM, Esquivel AO, Jin X, Yang KH, Onwudiwe NA and Vaidya R: Biomechanical stability of a supra-acetabular pedicle screw internal fixation device (INFIX) vs external fixation and plates for vertically unstable pelvic fractures. *J Orthop Surg Res* (2012) 7: 31.
11. Sar C and Kilicoglu O: S1 pediculoliliac screw fixation in instability of the sacroiliac complex: Biomechanical study and report of two cases. *J Orthop Trauma* (2003) 17: 262–270.
12. Berber O, Amis AA and Day AC: Biomechanical testing of a concept of posterior pelvic reconstruction in rotationally and vertically unstable fractures. *J Bone Joint Surg Br* (2011) 93: 237–244.
13. Toogood P, McDonald E and Pekmezci M: A Biomechanical comparison of ipsilateral and contralateral pedicle screw placement for modified triangular osteosynthesis in unstable pelvic fractures. *J Orthop Trauma* (2013) 27: 515–520.
14. Korovessis PG, Magnissalis EA and Deligianni D: Biomechanical evaluation of conventional internal contemporary spinal fixation techniques used for stabilization of complete sacroiliac joint separation: a 3-dimensional unilaterally isolated experimental stiffness study. *Spine* (2006) 31: 941–951.
15. Kobbe P, Hockertz I, Sellei RM, Reilmann H and Hockertz T: Minimally invasive stabilization of posterior pelvic-ring instabilities with a transiliac locked compression plate. *Int Orthop* (2012) 36: 159–164.
16. Santos ERG, Sembrano JN, Mueller B and Polly DW: Optimizing iliac screw fixation: a biomechanical study on screw length, trajectory, and diameter-Laboratory investigation. *J Neurosurg Spine* (2011) 14: 219–225.
17. Vialle R, Levessor N, Rillardon L, Templier A, Skalli W and Guigui P: Radiographic analysis of the sagittal alignment and balance of the spine in asymptomatic subjects. *J Bone Joint Surg Am* (2005) 87: 260–267.
18. Suzuki T, Shindo M, Soma K, Minehara H, Nakamura K, Uchino M and Itoman M: Long-Term functional outcome after unstable pelvic ring fracture. *J Trauma* (2007) 63: 884–888.
19. Lynn G, Mukherjee DP, Kruse RN, Sadasivan KK and Albright JA: Mechanical stability of thoracolumbar pedicle screw fixation. *Spine* (1997) 22: 1568–1573.