

Multiple Regression Analysis for Grading and Prognosis of Cubital Tunnel Syndrome: Assessment of Akahori's Classification

Masutaka Watanabe^{a*}, Seizaburo Arita^b, Hiroyuki Hashizume^c, Mitsugi Honda^d,
Keiichiro Nishida^e, and Toshifumi Ozaki^a

Departments of ^aOrthopaedic Surgery, and ^eHuman Morphology, Okayama University Graduate School of Medicine, Dentistry and Pharmaceutical Sciences, ^dDepartment of Central Division of Radiology, Okayama University Hospital, Okayama 700-8558, Japan, ^bDepartment of Faculty of Life and Medical Sciences, Doshisha University, Kyoto 714-0043, Japan, ^cDepartment of Kasaoka Hand & UE Center, Kasaoka Daiichi Hospital, Okayama 714-0043, Japan

The purpose of this study was to quantitatively evaluate Akahori's preoperative classification of cubital tunnel syndrome. We analyzed the results for 57 elbows that were treated by a simple decompression procedure from 1997 to 2004. The relationship between each item of Akahori's preoperative classification and clinical stage was investigated based on the parameter distribution. We evaluated Akahori's classification system using multiple regression analysis, and investigated the association between the stage and treatment results. The usefulness of the regression equation was evaluated by analysis of variance of the expected and observed scores. In the parameter distribution, each item of Akahori's classification was mostly associated with the stage, but it was difficult to judge the severity of palsy. In the mathematical evaluation, the most effective item in determining the stage was sensory conduction velocity. It was demonstrated that the established regression equation was highly reliable ($R = 0.922$). Akahori's preoperative classification can also be used in postoperative classification, and this classification was correlated with postoperative prognosis. Our results indicate that Akahori's preoperative classification is a suitable system. It is reliable, reproducible and well-correlated with the postoperative prognosis. In addition, the established prediction formula is useful to reduce the diagnostic complexity of Akahori's classification.

Key words: cubital tunnel syndrome, ulnar nerve, Akahori's classification, multiple regression analysis

Cubital tunnel syndrome is a series of symptoms induced by compression of the ulnar nerve in the peri-cubital tunnel region. Early symptoms include pain and numbness of the little and ulnar half of the ring fingers. Interosseous muscle atrophy and weakness occur as symptoms progress, and claw deformity

of the little and ring fingers and Froment's sign appear [1, 2]. For preoperative classification of the cubital tunnel syndrome, Akahori's and McGowan's [3] classifications are most commonly used in Japan, and McGowan's and Dellon's [4] classifications are most commonly used in Western countries. These classifications have individual characteristics, but no consensus has been reached regarding their superiority or inferiority. Akahori's classification was first reported in 1972 [5], and its revised edition incorpo-

rating electromyographic findings was reported in 1986 [6]. Evaluation items include clinical symptoms and the nerve conduction velocity (NCV), and these are divided into 2 sub items, sensory and motor nerves; the disease is classified into stages 1 to 5 (Table 1). This classification aims to clarify the severity of the symptoms. However, very few reports have investigated the usefulness of Akahori's classification. In this study, we mathematically evaluated the application of Akahori's classification system to cubital tunnel syndrome patients treated with cubital tunnel release using a small incision (simple decompression), and investigated the association between the stage and treatment results.

Materials and Methods

For the present analysis, we considered the results for 65 elbows with cubital tunnel syndrome that were treated with simple decompression by the same surgeon from 1997 to 2004. After excluding elbows with cubitus vulgus (1), rheumatoid arthritis (2), occupying lesions, such as ganglion cysts (4) and lipoma (1), 57 elbows (52 patients) remained and were entered into the analysis. The 52 patients consisted of 39 males and 13 females with an age range of 28 to 88 years (mean: 64.3 years). The follow-up period was 6 months to 3 years (mean: 10.5 months) after surgery. According to Akahori's preoperative classification by three hand specialists, the numbers of elbows were 3 in stage 1, 19 in stage 2, 17 in stage 3, 12 in stage 4, and 6 in stage 5.

The surgical indications [7] for cubital tunnel syndrome include night pain resistant to conservative

treatment for 1 month or longer and sensory disturbance of the ulnar nerve-innervated region without ulnar nerve dislocation but with positivity for Tinel's sign and the elbow flexion test as well as an electromyographic abnormality. All patients underwent cervical X-ray radiography, MRI, and electromyography before surgery, and the possibility of cervical vertebral lesions was ruled out.

The surgical procedure consisted of cubital tunnel release with a small skin incision (simple decompression) in which only Osborne's ligament was released [8, 9]. First, an approximately 2.5 cm skin incision was made directly on the ulnar nerve between the medial epicondyle and medial border of the olecranon. The subcutaneous tissue was carefully incised to expose the ulnar nerve. According to Osborne's method [10, 11], Osborne's ligament, the proximal medial intermuscular septum, and the superficial fascia of the proximal side of the flexor carpal ulnaris were released in this order. The points of adhesion of the ulnar nerve to tissue around the cubital tunnel were carefully separated while avoiding injury to the feeding blood vessels. Only the medial epicondylar side of the ulnar nerve was dissected; the olecranon side was not. During this procedure, a broad area around the ulnar nerve could be directly visualized via the small incision. This effort was assisted by sufficiently dissecting the subcutaneous region, employing the window technique to maintain the visual field by retracting the dissected region using hooks, and placing a pillow under the elbow and adjusting the elbow position (Fig. 1). After decompression, the elbow was flexed and extended to confirm the absence of ulnar nerve dislocation. After surgery, elastic ban-

Table 1 Akahori's classification according to preoperative factors

Stage	Clinical symptoms				Nerve conduction velocity	
	Sensory nerve	Motor Nerve			Sensory nerve	Motor nerve
		Muscle atrophy	Muscle weakness	Finger deformity		
1	Elbow flexion test (+), hypesthesia (±)	1st dorsal interossei only (±)	(±)	(-)	Normal	Normal
2	Hypesthesia (+)	1st dorsal interossei only (±) Others (±)~(+)	(±)	(±)	Diminished	Normal
3	Hypesthesia (+)	(+)	(+)	(±)~(+)	Diminished, occasionally disappeared	Almost normal or diminished
4	Hypesthesia (++) occasionally analgesia	(++)	(++)	(++)	Disappeared	Diminished
5	Hypesthesia (++) almost analgesia	(++)	(++)	(++)	Disappeared	Diminished, occasionally disappeared

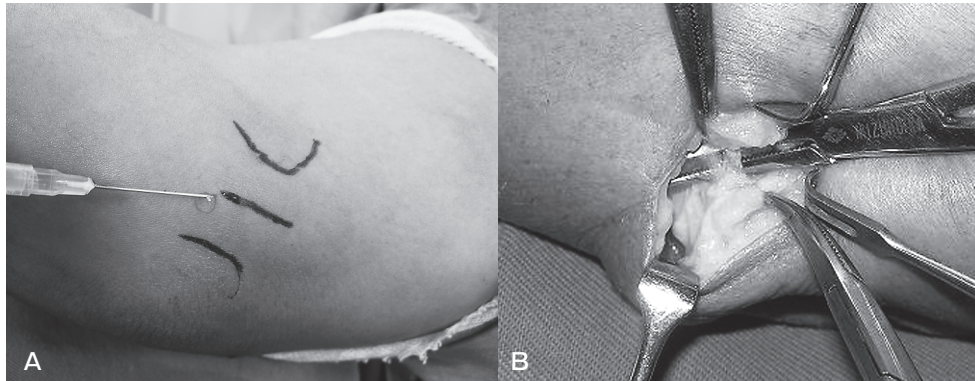

Fig. 1 Surgical procedure for the release of Osborne's ligament with a small incision using window technique. **A**, Local anesthesia was done on the cubital tunnel between the medial epicondyle and the medial border of the olecranon; **B**, Osborne's ligament was released.

dage fixation was applied, and active movement of the elbow joint was initiated after 2–3 days.

The following were examined in the 57 elbows: night pain, sensory disturbance, atrophy of the thumb adductor, hypothenar muscles, and dorsal interosseous muscle, weakness of the opposing muscle of the little finger, thumb adductor, and little and ring finger flexors, claw finger deformity, Froment's and Tinel's signs, and distal motor latency (DML), motor nerve conduction velocity (MCV), and sensory nerve conduction velocity (SCV) in the cubital tunnel on electromyography. Electromyography was performed by the same operator using the same device for all patients. The status of these items was recorded on a checkup list both before and 6 months after surgery. The surgical results were evaluated using Akahori's evaluation criteria [6] as excellent (complete resolution of symptoms with no postoperative motor or sensory deficits, or with minimal sensory deficits), good (general resolution of symptoms with residual decreased sensibility and residual motor weakness), fair (improvement after surgery but with persistent sensory changes, residual motor loss, muscle wasting, or persist claw deformity), or poor (no improvement after the surgical procedure, or worsening).

Multiple regression analysis. Items used for Akahori's classification were extracted from those in the checkup list and categorized (Table 2). Sensory disturbance, absence or numbness only in the fingertips was categorized as 0, and numbness in the fingertips and other regions was categorized as 1. For pain, the absence or presence of night pain was categorized as 0 or 1, respectively. In the case of muscle atro-

phy, since quantitative evaluation was difficult, the categorization was based on the total number of three muscle sites – the thumb adductor, hypothenar, and dorsal interosseous muscles – that showed atrophy (0: absent; 1: one site; 2: 2 sites; 3: 3 sites). Quantitative evaluation of muscle weakness was categorized based on the total number of muscle sites showing weakness among the above 3 sites (0: absent; 1: one site; 2: 2 sites; 3: 3 sites; 4: 4 sites). Claw finger deformity was categorized as 0 or 1 based on the absence or presence of deformity, respectively. The sensory and motor nerves were categorized based on the difference between the cubital tunnel and distal levels on electromyography (0: less than 10m/s; 1: 10m/s or higher; 2: denervation potential).

Based on the categorized findings, Akahori's classification was statistically evaluated as follows:

1. The preoperative relationship between each item (clinical symptoms: $n = 57$; NCV: $n = 55$) and stage was investigated based on the parameter distribution. Because there were missing values, 2 cases in the NCV group were excluded.
2. The relationships between items of Akahori's classification and between categories in each item (pain, sensory disturbance, muscle atrophy, finger deformity, SCV, and MCV) were analyzed. Multivariate analysis was performed on 112 elbows (before surgery: 55 elbows; after surgery: 57 elbows) using the Akahori's classification as a dependent variable and the items of Akahori's classification as independent variables, by employing the mathematical quantification theory class I. In the analysis, categories 0 and

Table 2 Category of subjects according to item of Akahori's classification

Preoperative factors			Category			
			0	1	2	3
Clinical symptoms Sensory	Sensory disturbance		absent or tip of fingers	+		
	Night pain		-	+		
Clinical symptoms Motor	Muscle atrophy	The number of atrophic muscles (AP, Hyp, DI)	absent	1 site	2 sites	3 sites
	Muscle weakness	The number of weak muscles (AP, Hyp, DI, 5F)	absent or 1 site	2 sites	3 sites	4 sites
	Finger deformity	Claw deformity	-	+		
NCV	SCV	A conduction difference between osborne level and distal level (m/s)	0 < 10	≥10	disappear	
	MCV	A conduction difference between osborne level and distal level (m/s)	0 < 10	≥10	disappear	

NCV, nerve conduction velocity; SCV, sensory nerve conduction velocity; MCV, motor nerve conduction velocity; AP, adductor pollicis; Hyp, hypothenar; DI, dorsal interosseous; 5F, flexor digitorum profundus of the little finger.

1 of muscle atrophy were combined, as well as categories 2 and 3. Because there were few parameters for the Stage 4 and Stage 5 cases, these cases were combined. Colinearity between items was ruled out by analysis of variance. The significance of each item on Akahori's classification was determined by the size of its range on the category score graph. The between-category relationship in each item was evaluated based on the category score. The usefulness of the obtained regression equation was evaluated by analysis of variance of the expected and observed scores. For the mathematical quantification theory, EXCEL mathematical quantification theory ver. 3.0 was used.

3. Using the regression equation of preoperative Akahori's classification established above, we examined the degree of improvement of clinical paralysis for target cases. In addition, cases in which the outcome of simple decompression was judged as fair or poor based on Akahori's postoperative evaluation criteria were clinically evaluated.

The above analyses were performed using SPSS11.0J for Windows, and values of $p < 0.05$ were regarded as statistically significant.

Results

Clinical results. The surgical results accord-

ing to Akahori's postoperative evaluation criteria were excellent, good, fair and poor, in 33, 16, 6 and 2 elbows, respectively. One of the poor cases was a patient with Akahori's classification stage 5 accompanied by osteoarthritis of the elbow with end-stage deformity. Since pain persisted and palsy progressed after surgery, anterior nerve transposition of the ulnar nerve was performed 3 months after surgery, and a favorable outcome was finally achieved. In the other cases, no postoperative complications, including hematoma, skin disorder, infection, rapid progression of palsy, or complex regional pain syndrome, occurred.

Investigation by items of Akahori's classification.

1. Clinical symptoms

Sensory disturbance was observed in all cases staged 1-5 using Akahori's classification. Night pain was reported in all cases excluding one elbow. No atrophic muscle was noted in stage 1, and the atrophic muscle region gradually increased as the stages progressed from 2 to 4. In stage 5, 3 or more atrophic muscle regions were present in all cases. In stage 3, dispersion of the parameter distribution was noted. The number of weak muscle sites was approximately 1 in stage 1 and increased as the stage progressed from 2 to 5. In stage 2, the parameter distribution was less

clear. The distribution of finger deformity was correlated with the stage (Table 3a).

2. Nerve conduction velocity

The distribution of MCV was correlated with the stage, but no apparent difference was noted between stages 2 and 3. The distribution of SCV was mostly associated with the stage. Denervation potential was observed primarily in stages 4 and 5. In stage 3, the parameter distribution was less clear (Table 3b).

Multiple regression formula of Akahori's classification. The following findings were obtained by the regression equation in regard to the preoperative factors of Akahori's classification as independent variables (Table 4). The ranges of each item were organized in ascending orders: SCV, 0.777;

sensory disturbance, 0.655; MCV, 0.642; muscle atrophy, 0.539; claw finger deformity, 0.415; and night pain, 0.313.

The trend of change in each item based on the category score graph was as follows (Fig. 2). In all items, the score tended to show rising with category progression, but the relationship between the category and score was not linear in MCV or SCV, and the score was markedly higher in category 2.

The interaction between items was investigated based on the scores. The early stages were influenced by sensory disturbance and muscle atrophy, whereas the end stage was influenced by SCV and MCV.

In the analysis of variance of the theoretical and measured values, $R = 0.922$. The difference between

Table 3 Distribution of preoperative factors according to Akahori's classification

a. Clinical symptoms (n = 57)

Stage		Sensory disturbance		Night pain		Finger deformity	
		-	+	-	+	-	+
1		0	3	0	3	3	0
2		0	19	0	19	16	3
3		0	17	1	16	9	8
4		0	12	0	12	3	9
5		0	6	0	6	0	6
n		0	57	1	56	31	26

Stage		Muscle atrophy				Muscle weakness			
		absent	1 site	2 sites	3 sites	absent or 1site	2 sites	3 sites	4 sites
1		3	0	0	0	3	0	0	0
2		11	5	1	2	6	3	7	3
3		3	3	5	6	2	2	9	4
4		0	0	3	9	0	0	3	9
5		0	0	0	6	0	0	2	4
n		17	8	9	23	11	5	21	20

b. Nerve conduction velocity (n = 55)

Stage		Mortor nerve (m/s)			Sensory nerve (m/s)		
		0 < 10	≥ 10	disappear	0 < 10	≥ 10	disappear
1		2	1	0	1	2	0
2		6	12	0	7	10	1
3		5	11	0	4	7	5
4		0	11	1	1	0	11
5		0	0	6	0	0	6
n		13	35	7	13	19	23

Table 4 Multi-regression formula according to Mathematical quantification theory class I for Akahori's classification

X			Y	
independent variable	category		statistical method	dependent variable
X ₁	Sensory disturbance	X ₁₁ ; absent or tip of fingers	mathematical quantification theory class I	→ Akahori's classification
		X ₁₂ ; +		
X ₂	Night pain	X ₂₁ ; -		
		X ₂₂ ; +		
X ₃	Muscle atrophy	X ₃₁ ; absent or 1 site		
		X ₃₂ ; more than 2 sites		
X ₄	Finge deformity	X ₄₁ ; -		
		X ₄₂ ; +		
X ₅	MCV	X ₅₁ ; ¶ < 10 m/s		
		X ₅₂ ; ¶ ≥ 10 m/s		
		X ₅₃ ; disappeared		
X ₆	SCV	X ₆₁ ; ¶ < 10 m/s		
		X ₆₂ ; ¶ ≥ 10 m/s		
		X ₆₃ ; disappeared		

$$\begin{aligned}
 Y = & (-0.439) X_{11} + 0.216 X_{12} \\
 & + (-0.165) X_{21} + 0.148 X_{22} \\
 & + (-0.231) X_{31} + 0.308 X_{32} \\
 & + (-0.119) X_{41} + 0.297 X_{42} \\
 & + (-0.137) X_{51} + 0.044 X_{52} + 0.506 X_{53} \\
 & + (-0.249) X_{61} + (-0.229) X_{62} + 0.528 X_{63} \\
 & + 2.250
 \end{aligned}$$

MCV, motor nerve conduction velocity; SCV, sensory nerve conduction velocity; ¶, the difference between the cubital tunnel and distal levels on electromyography. Dependent variable is a grand total of each category coefficients correspond to clinical dates.

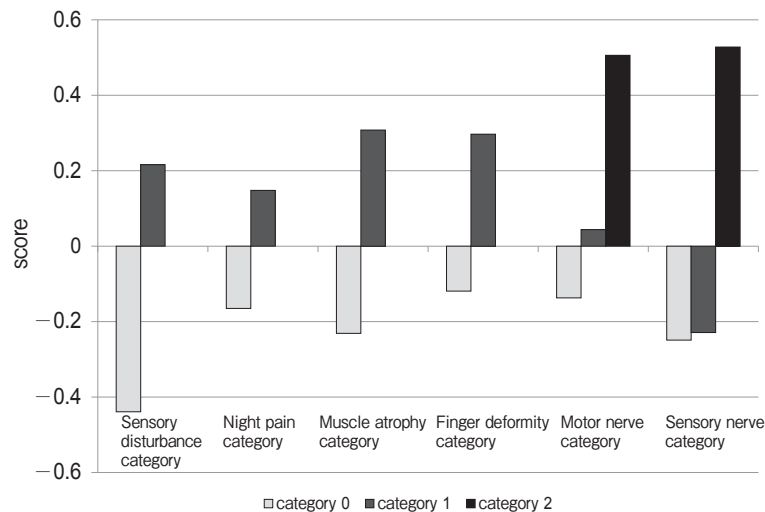


Fig. 2 Category score graph. This figure shows relations of between-item and within-item evaluations score based on the mathematical quantification theory class I result. Range is the modulus grand total of the maximum and the minimum score.

the observed and expected values was 0.5 or greater in 25 out of the 112 elbows (Table 5).

Comparison of clinical findings and Akahori's classification. The resulting stages were determined by comparing the pathology at 6 months after surgery using the above regression equation (postoperative classification) and preoperative stages of classification in order to investigate the trends in their relationship. Most cases of preoperative stage 1-3 of Akahori's classification were improved to stage 1 or 2 at 6 months after surgery. Preoperative stage 4-5 cases were improved, but 3 of 12 preoperative stage 4 cases remained in stage 3. No improvement to stage 1 or 2 was noted in any preoperative stage 5 case. The postoperative stage judged based on Akahori's classification showed a trend of association

with Akahori's postoperative evaluation criteria, although the correlation was not statistically significant. Postoperative stages 1, 2, 3, and 4/5 of Akahori's classification were roughly associated with excellent, good, fair, and poor ratings on Akahori's postoperative evaluation criteria, respectively (Table 6).

The outcome of simple decompression judged by employing Akahori's postoperative evaluation criteria was fair and poor in 8 elbows, and the clinical preoperative Akahori's classifications of these cases were stages 4 and 5 in 3 and 5 elbows, respectively. Five of these 8 elbows were accompanied by severe osteoarthritis. The outcome was fair or poor in 5 of the 6 preoperative stage-5 elbows. Eighteen elbows were accompanied by severe osteoarthritis, and the outcome was fair or poor in 5 of these (27.8%). In addition, the outcome tended to be fair or poor in cases with severe muscle atrophy and denervation potential on electromyography.

Case 1. The patient was a 46-year-old male with night pain and sensory disturbance of the ulnar nerve-innervated region of the hand. The duration of illness was 3 months. Hypothenar and dorsal interosseous muscle atrophy was present, and 8.9 and 9.8m/s delays were noted in MCV and SCV, respectively. The observed and expected stages of Akahori's classification were 3 and 2.834 ($Y = 0.216 + 0.148 +$

Table 5 Correlation between the observed stage and expected stage of Akahori's classification

Akahori's classification		Observed stage			
		1	2	3	4 or 5
Expected Stage	1	28	1		
	2	10	27	5	
	3		2	16	4
	4 or 5			1	18

R² = 0.851 (n = 112)

Table 6 Relation between the pre- and postoperative Akahori's classification and Akahori's postoperative evaluation criteria

Pre-operative Akahori's classification	Post-operative Akahori's classification	Akahori's postoperative evaluation criteria (n)			
		excellent	good	fair	poor
1 (n = 3)	1 (n = 3)	3			
2 (n = 19)	1 (n = 18)	15	3		
	2 (n = 1)	1			
3 (n = 17)	1 (n = 10)	10			
	2 (n = 6)	1	5		
	3 (n = 1)			1	
4 (n = 12)	1 (n = 4)	3	1		
	2 (n = 5)		4	1	
	3 (n = 3)		2	1	
5 (n = 6)	3 (n = 2)		1	1	
	4 (n = 3)		1	2	
	5 (n = 1)				1

(n = 57)

$0.308 + 0.297 - 0.137 - 0.249 + 2.250 = 2.834$), respectively. At 6 months after surgery, pain and numbness disappeared, but the hypothenar muscle atrophy remained, and 1.8 and 7.2 m/s delays were noted in MCV and SCV, respectively. The outcome based on Akahori's postoperative evaluation criteria was excellent. The observed and expected stages of Akahori's classification were 1 and 0.911 ($Y = -0.439 - 0.165 - 0.231 - 0.119 - 0.137 - 0.249 + 2.250 = 0.911$), respectively, showing consistency between the observed and expected scores using Akahori's classification.

Case 2. The patient was a 50-year-old male with night pain and sensory disturbance of the ulnar nerve-innervated region of the hand. The duration of illness was 6 months. Dorsal interosseous muscle atrophy was present, and 16.7 and 31.8 m/s delays were noted in MCV and SCV, respectively. The observed and expected stages of Akahori's classification were 3 and 2.081 ($Y = 0.216 + 0.148 - 0.231 - 0.119 + 0.044 - 0.229 + 2.250 = 2.081$), respectively. At 6 months after surgery, pain and numbness disappeared, no hypothenar muscle atrophy remained, and 2.8 and 5.4 m/s delays were noted in MCV and SCV, respectively. The outcome based on Akahori's postoperative evaluation criteria was favorable. The observed and expected stages of Akahori's classification were 1 and 0.911 ($Y = -0.439 - 0.165 - 0.231 - 0.119 - 0.137 - 0.249 + 2.250 = 0.911$), respectively, showing inconsistency between the observed and expected scores using this classification.

Discussion

The methods used for clinical classification of cubital tunnel syndrome are diverse, but few of these approaches provide a quantitative evaluation. Asami *et al.* [12] defined useful preoperative classification as follows: The preoperative classification system should be simple, reliable, reproducible, and well-correlated with the postoperative prognosis. The commonly used McGowan classification is simple, but the vagueness of the classification and poor correlation with the outcome of surgery were pointed out by Froimson [13] and Leffert [14] (data not shown). In our own practice, we have used the preoperative staging by Akahori's classification, and have generally found that is clinically useful. Accordingly, we evaluated Akahori's classification mathematically, and investi-

gated its usefulness as a clinical stage classification system.

The main advantage of Akahori's classification is that both items involving subjective evaluation, such as muscle atrophy, and items involving objective evaluation by electromyography are collected. Thus, we investigated the tendency of each item to utilizing Akahori's classification.

Based on the distribution map of each preoperative factor of Akahori's classification, all items tended to be slowly aggravated along with the stage progression from 1 to 5 of Akahori's classification. Unexpectedly, although the severity of muscle atrophy was evaluated based on clinically subjective observations, the stage tended to accurately represent the pathology. This tendency confirmed the established reputation of this classification system for the evaluation of preoperative muscle atrophy severity and outcomes of surgery. McGowan, Foster, and Jensen have also previously stated that the presence of intrinsic muscle atrophy preoperatively is a poor prognostic sign [3, 15, 16]. In the distribution map, dispersion was noted in each item, mainly stages 2 and 3 of Akahori's classification, showing that it is difficult to judge the severity of palsy in cubital tunnel syndrome, which is a collective term for various symptoms caused by entrapment of the ulnar nerve.

Each item of Akahori's classification tended to show stepwise progression of palsy with stage progression, but it was difficult to identify the accurate pathology based on a single item. To judge the severity of palsy in cubital tunnel syndrome, comprehensive judgment of palsy-related items is necessary. To make a comprehensive judgment, it is necessary to investigate how the items are organically involved with each other.

As another characteristic of Akahori's classification, the items are qualitative, but not quantitative. When the data are qualitative, the relationship among the categories may not be linear, and thus evaluation of the trends within individual items may be necessary, in addition to evaluation of the organic involvement of items with each other. Thus, in the multivariate analysis, we employed a regression equation established using the mathematical quantification theory class I, which is capable of inter- and intra-item evaluations.

The established regression equation showed consis-

tency with the clinical subjectivity, demonstrating the reliability of Akahori's classification. Concretely, the item most markedly influential for staging was NCV including SCV and MCV. NCV is quantitative, unlike other items in Akahori's classification, which may have increased its influence. The factors determining the severity of early and end-stage palsy in cubital tunnel syndrome were different. In the early to middle stage, sensory disturbance and muscle atrophy influenced staging, whereas SCV and MCV influenced the determination of the middle to end stage. Based on the above findings, NCV serves as a stage-determining item when the pathology of cubital tunnel syndrome becomes aggravated, but, when the pathology is relatively mild, clinical symptoms serve as stage-determining items, rather than electromyographic findings. Since Akahori's classification is comprised of items of subjectivity-based clinical symptoms and objective data-based nerve conduction velocity, reliable staging is possible from the early through the end stages of cubital tunnel syndrome.

Asami *et al.* [12] pointed out problems with Akahori's classification: the classification is complex, and the electromyographic and clinical findings are inconsistent in some cases. In our patients, the theoretical and measured values deviated in some cases, particularly on the differentiation of stage 2, and differences were noted between the muscle atrophy severity and electromyographic findings in most cases showing deviation. For example, in cases staged 2 in which 3 or atrophic muscle sites were present but the electromyographic data was not notably decreased, the theoretical value was close to that of stage 3, showing that when there is a difference between the clinical symptoms and nerve conduction velocity, it is difficult to determine the stage of Akahori's classification, and reproducibility may decrease. It was demonstrated that the established regression equation was highly reliable ($R = 0.922$), and thus this equation is likely to be useful for predicting the Akahori's classification. By using this prediction formula, complex staging employing Akahori's classification may be simplified and the reproducibility may be increased.

In addition, it was demonstrated that Akahori's classification is reflected in the outcome of surgery. We applied the regression equation of Akahori's classification to the outcome of surgery to investigate whether it can be utilized as a postoperative criterion.

Akahori's classification applied after surgery and Akahori's postoperative evaluation criteria were correlated to some extent. The consistency of the correlation was incomplete, and this may have been due to the subjectivity of the observer in Akahori's criteria for postoperative evaluation. Although Akahori's classification is useful to investigate changes in the severity of palsy after surgery, the postoperative effect cannot be evaluated based on severity of the symptoms alone. The level of patient satisfaction with treatment, which is independent from the severity of the symptoms, is also reflected in the postoperative evaluation criteria.

Based on the above discussion of Akahori's classification, we considered the simple decompression operation procedure from a clinical point of view as follows: Akahori's classification is to be used to identify the palsy severity after cubital tunnel syndrome is diagnosed, and when NCV shows denervation potential. When Akahori's classification stage is 4 or 5, the application of simple decompression is difficult. To confirm Akahori's classification stages 1–3, which are an indication for the simple decompression procedure, clinical symptoms are important. Clinicians should sufficiently investigate the muscles innervated by the ulnar nerve to examine the severity of the muscle atrophy and patient's chief complaint. They should try to avoid missing the timing of progression from Akahori's classification stage 3 to 4. Mowlavi *et al.* pointed out the necessity of accurately identifying the stage to select surgical management for cubital tunnel syndrome [17], for which Akahori's classification may be useful to decide on application of simple decompression.

In conclusion, the disease stage is classified in a stepwise manner with the severity in Akahori's classification to clarify the palsy severity in cubital tunnel syndrome, and items important to evaluate palsy are available. Therefore, Akahori's classification-based diagnostic criteria may be useful not only for the judgment of the disease severity, but also for the prediction of the surgical result. In addition, the established prediction formula is useful to reduce the diagnostic complexity of Akahori's classification.

References

1. Britz GW, Haynor DR, Kuntz C, Goodkin R, Gitter A, Maravilla K

- and Kliot M: Ulnar nerve entrapment at the elbow: correlation of magnetic resonance imaging, clinical, electrodiagnostic, and intraoperative findings. *Neurosurgery* (1996) 38: 458-465.
2. Dawson DM: Entrapment neuropathies of the upper extremities. *N Engl J Med* (1993) 329: 2013-2018.
 3. McGowan AJ: The results of transposition of the ulnar nerve for traumatic ulnar neuritis. *J Bone Joint Surg Br* (1950) 32: 293-301.
 4. Dellon AL: Review of treatment results for ulnar nerve entrapment at the elbow. *J Hand Surg* (1989) 14: 688-700.
 5. Akahori O, Urakami M, Mizuno I, Nishiyama T, Sakane M, Dohi N, Kikuyama M, Takasugi J and Akashi K: Early diagnosis and treatment for tardy ulnar nerve palsy. *Seikeigeka* (1972) 23: 94-102 (in Japanese).
 6. Akahori O: Cubital tunnel syndrome Grade of palsy and prognosis, and selection of operation. *Seikeigeka* (1986) 29: 1745-1751 (in Japanese).
 7. Novac CB, Lee GW, Mckinnon SE, Lay L and Louis St: Provocative testing for cubital tunnel syndrome. *J Hand Surg Am* (1994) 19: 817-820.
 8. Taniguchi Y, Takami M, Tamaki T and Yoshida M: Simple decompression with small skin incision for cubital tunnel syndrome. *J Hand Surg Br* (2002) 27: 559-562.
 9. Nagaoka M: Treatment of cubital tunnel syndrome with small skin incision. *Seikeigeka* (2007) 50: 533-537 (in Japanese).
 10. Feindel W and Stratford J: Cubital compression in tardy ulnar nerve palsy. *Can Med Assoc J* (1958) 78: 351-353.
 11. Osborne G: Compression neuritis of the ulnar nerve at the elbow. *Hand* (1970): 10-13.
 12. Asami A: The evaluation of a pre- and post-operative classification system for cubital tunnel syndrome. *Hand Surg* (2001) 6: 187-190.
 13. Froimson AI and Zahrawi F: Treatment of compression neuropathy of the ulnar nerve at the elbow by epicondylectomy and neurolysis. *J Hand Surg Am* (1980) 5: 391-395.
 14. Leffert RD: Anterior submuscular transposition of the ulnar nerves by the Learmonth technique. *J Hand Surg Am* (1982) 7: 147-155.
 15. Foster RJ and Edshage S: Factors related to the outcome of surgically managed compressive ulnar neuropathy at the elbow level. *J Hand Surg Am* (1981) 6: 181-192.
 16. Jensen E: Ulnar perineuritis; a survey with a follow-up examination of 39 operated cases. *Acta Psychiatr Neurol Scand* (1959) 34: 205-221.
 17. Mowlavi A, Andrews K, Lille S, Zook EG and Milner S: The management of cubital tunnel syndrome: a meta-analysis of clinical studies. *Plast Reconstr Surg* (2000) 106: 327-334.