

Dentistry
Dentistry fields

Okayama University

Year 2003

Application of dynamic
contrast-enhanced MRI to differentiate
malignant lymphoma from squamous cell
carcinoma in the head and neck

Jun-ichi Asaumi*

Yoshinobu Yanagi†

Hironobu Konouchi‡

Miki Hisatomi**

Hidenobu Matsuzaki††

Kanji Kishi‡‡

*Okayama University, asaumi@md.okayama-u.ac.jp

†Okayama University

‡Okayama University

**Okayama University

††Okayama University

‡‡Okayama University

This paper is posted at eScholarship@OUDIR : Okayama University Digital Information Repository.

http://escholarship.lib.okayama-u.ac.jp/dentistry_general/5

Application of dynamic contrast-enhanced MRI to differentiate malignant lymphoma from squamous cell carcinoma in the head and neck

Jun-ichi Asaumi, Yoshinobu Yanagi, Hironobu Konouchi, Miki Hisatomi, Hidenobu Matsuzaki, Kanji Kishi.

Department of Oral and Maxillofacial Radiology, Field of Tumor Biology,
Graduate School of Medicine and Dentistry, Okayama University

Address correspondence to Jun-ichi Asaumi, Department of Oral and Maxillofacial Radiology, Field of Tumor Biology, Graduate School of Medicine and Dentistry, Okayama University, 2-5-1, shikata-cho, Okayama 700-8525, JAPAN.

Telephone number: +81-86-235-6705

Fax number: +81-86-235-6709

E-mail: asaumi@md.okayama-u.ac.jp

Keywords: DCE-MRI, head and neck, lymphoma, squamous cell carcinoma, contrast index curve

Abstract

Because malignant lymphoma, the second most common malignant tumor of the head and neck, and squamous cell carcinoma (SCC), the most common malignant tumor of the head and neck, require different treatments, it is important to be able to differentiate them. In the present study, we attempted to differentiate malignant lymphomas from SCCs using dynamic contrast-enhanced MRI (DCE-MRI). Seventeen lesions (in 8 cases) of malignant lymphoma and 30 cases of SCC were compared by DCE-MRI.

Thirteen of 17 malignant lymphomas (76.5 %) showed the maximum contrast index (CI) at 90-180 s, while 26 of 30 SCCs (86.7%) showed the maximum CI at a much faster 60-105 s. There was a statistically significant difference between SCC and malignant lymphoma in the time needed reach the maximum CI ($p=0.0177$). There was also significant difference between SCC and malignant lymphoma in their maximum CIs ($p<0.001$), with the maximum CIs of 29/30 SCCs (96.7%) above 2.0, while 12/17 malignant lymphomas (70.6%) showed CIs of less than 2.0. We consider these findings to be useful for distinguishing lymphomas from SCCs.

Keywords: DCE-MRI, head and neck, lymphoma, squamous cell carcinoma, CI curve

Keywords: DCE-MRI, head and neck, lymphoma, squamous cell carcinoma, contrast index curve

1. Introduction

Malignant lymphoma is the second most common malignant tumor of the head and neck, and is treated by chemotherapy, radiotherapy, or a combination of these. For squamous cell carcinoma (SCC), the most common malignant tumor of the head and neck, surgery is usually the performed treatment. Because malignant lymphomas and SCCs require different treatments, it is important to be able to differentiate them.

MRI is effective for diagnosing tumors and has some advantages over traditional techniques, especially in detecting soft tissue lesions [1, 2]. However, MRI examination has not yet come into use for the differential diagnosis of tumors. Therefore, plain MR signals often cannot contribute to a differential diagnosis or to be used to determine whether a tumor is benign or malignant. It has been reported that dynamic contrast-enhanced MRI (DCE-MRI) is useful for the differential diagnosis of some tumors, and many investigators have attempted to use it to identify differences

between benign and malignant tumors, as well as to assess the malignancy of tumors [3-6]. We have also reported the usefulness of DCE-MRI for tumor diagnosis [7-9]. Nevertheless, there have been few reports to date of DCE-MRI used in malignant lymphoma and/or SCC of the head and neck for diagnostic or predictive purposes. In the present study, we attempted to differentiate malignant lymphomas from SCCs in the head and neck using DCE-MRI.

2. Materials and methods

2.1. Materials

Thirty patients with primary head and neck SCC (Table 1) and 8 patients (17 lesions) with malignant lymphoma (Table 2) underwent DCE-MRI at our hospital, the SCC patients between 1997 and 1999, and the lymphoma patients between 1999 and 2002. All subjects gave their informed consent. The SCC patient population consisted of 14 females and 16 males regarding in age from 47 to 93 years old (mean, 69.3 years old). The lymphoma patients were 1 female and 7 males who were between 50 and 82 years old (mean, 63.6 years old). There was no significant difference between SCC and malignant lymphoma patients in age distribution ($p=0.1876$). The primary site distribution of SCC was as follows: tongue, 9; upper gingival, 6; lower gingival, 6; floor of mouth, 4; cheek, 3; from cheek to lower gingival, 1; and from tongue to pharynx, 1. The distribution of the 17 lymphoma lesions was as follows: submandibular region, 8; palate, 1; tonsil, 1; buccal, 3; orbit, 2; submental, 2 (Tables 1 and 2).

2.2. MR sequence

The MR examination was performed on a 1.5 T unit (Magnetom Vision; Siemens, Erlangen, Federal Republic of Germany) with a CP head coil or a head-neck coil. Routine T1- and T2-weighted images were acquired with spin-echo and turbo spin-echo sequences with frequency-selective fat-suppression in the transverse and the coronal planes, respectively. For DCE-MRI, 21 consecutive data sets were acquired for 315 sec (14 sec/1 scan) with three-dimensional fast imaging with steady state precession (repetition time / echo time /flip angle=5/2/25 degree, 16 slices for 48 mm of a slab thickness, resulting in 3 mm of effective slice thickness) and frequency-selective fat-suppressed T1-weighted images were immediately acquired as contrast-enhanced T1-weighted images. Intravenous injection of Gd-DTPA (Magnevist; Nihon Schering,

Osaka, Japan) was archived manually at a rate of approximately 2 ml / sec through a 21-gauge butterfly needle inserted into a vein in the cubital fossa. The injection of a contrast medium started 6 sec before the initiation of a second scan of 21 DCE-MRI data sets. The DCE-MR images were acquired repeatedly at 600, 615, 900, and 915 sec after the start of the injection of contrast medium.

2.3. Data analysis

A region of interest (ROI) was drawn to include the whole mass area selected from post-contrast images. The mean signal intensity (SI) of the ROIs was then measured on the monitor using the electric cursor. Contrast index (CI) versus time curves (CI-curves) were drawn. CI was calculated by the following formula: $CI=(SI_t-SI_0)/SI_0$, where SI_t is the mean signal intensity at the time t after the injection of contrast medium, and SI_0 is the mean signal intensity before the injection of contrast medium.

2.4. Statistical analysis.

Statistical analysis of the relationship between the maximum CI of SCC and that of lymphoma was carried out using StatView software (for Macintosh, Version 5.0, SAS Institute Inc., San Francisco, CA, USA). Statistical significance was assessed by the Students t-test and p values of <0.05 were considered to be significant.

3. Results

The CI curves of malignant lymphoma and SCC, calculated from a dynamic series, are shown in Figures 1 and 2, respectively. Of 17 curves of malignant lymphoma, 14 (82.4%) increased rapidly, followed by a relatively rapid initial decrease and a gradual decrease thereafter. The remaining 3 cases (17.6%) had no apparent peak, reaching a maximum CI and sustaining a temporary plateau, followed by a gradual decrease thereafter. Thirteen curves of malignant lymphoma (76.5%) reached their maximum CI at 90-180 s and the remaining 4 curves (13.5%) reached maximum CI at 45-60 s. Although the maximum CIs of 5 the malignant lymphomas lesions (29.4%) were beyond 2.0, 12 curves (70.6%) showed CIs of less than 2.0. The appearance of multiple lesions is one of the characteristic findings of malignant lymphoma, and the CI curves of the multiple lesions of individual patients showed similar patterns.

All CI curves of SCCs showed a pattern of rapid increase followed by rapid initial

decrease and gradual decrease thereafter. The time needed to reach the maximum CI of 26/30 SCCs (86.7%) was 60-105 s and tended to be rapid compared with that of malignant lymphomas. The maximum CIs of 29/30 SCCs (96.7%) were above 2.0.

The relationship between the maximum CI and the time needed to reach the maximum CI is plotted in Figure 3. Of 17 malignant lymphoma lesions in 8 patients, 3 lesions (in 2 patients) could not be differentiated from SCC lesions, but the remaining 14 lesions (82.4%) were successfully differentiated from SCC lesions on the basis of the line drawn in the Figure 3. Furthermore, the mean maximum CI of SCC was 2.88 ± 0.60 (range, 1.82-4.11), while the mean maximum CI of malignant lymphoma was 1.96 ± 0.86 (range, 0.98-4.24), a statistically significant difference ($p < 0.001$) (Tables 1 and 2). We also found a significant difference ($p = 0.0177$) in the mean times for reaching maximum CI, which were 97.1 ± 38.3 and 78.5 ± 29.1 in SCC and malignant lymphoma patients, respectively.

4. Discussion

Dynamic features show the characteristic features of tumors and may be useful for making a differential diagnosis. DCE-MRI may therefore be useful in diagnosing some tumors and in predicting their biological behavior. However, there have been few reports to date of DCE-MRI used diagnostic or predictive purposes in cases of tumors of head and neck. Although there have been a few reports on the basis of DCE-MRI in malignant lymphoma and SCC patients, [10, 11], there has been no report to date on the use of DCE-MRI for the purpose of distinguishing between these lesions. In the present study, we examined the usefulness of DCE-MRI for differentiating lymphomas from SCCs using the CI curve. The CI curves 76.5% of malignant lymphoma showed a maximum CI at 90-180 s, while those of 86.7% of SCCs were more rapid at a maximum CIs of 60-105 s. There is a thus significant difference between malignant lymphoma and SCC in the time needed to reach the maximum CI ($p = 0.0177$). Furthermore, the maximum CIs of 28/29 SCCs (96.6%) were above 2.0, while 12/17 lymphomas (70.6%) showed CIs of less than 2.0; the maximum CIs was thus significantly larger in SCCs compared with malignant lymphomas ($p < 0.001$). In malignant lymphoma, there were 3/17 lesions (17.6 %) whose time to reach the maximum CI was within 105 s and whose maximum CI was above 2.0. In SCCs, there were no lesions in which the time to reach the maximum CI was more than 90 s and whose maximum CI was less than 2.0. Thus, DCE-MRI might useful for distinguishing malignant lymphomas from SCCs. In the present study, when the relationship between the maximum CI and the time needed to

reach the maximum CI was plotted, 14 of 17 malignant lymphoma lesions (82.4%) were clearly distinct from SCC lesions. We therefore believe that DCE-MRI might be useful for distinguishing malignant lymphomas from SCCs.

Acknowledgement

This work was supported by a Grant-in-Aid for Scientific Research on Priority Areas of Okayama University and Grant-in-Aid (14370603, 14771037, 14771038) for Scientific Research from the Ministry of Education, Science, Sports and Culture of Japan.

References

- [1] Sipro RH: Management of malignant tumors of the salivary glands. *Oncology* 1998; 12:671-80.
- [2] Joe VQ, Weatesson P-L: Tumors of the parotid gland: MR imaging characteristics of various histologic types. *AJR* 1994;163:433-8.
- [3] Ikarashi F, Nakano Y, Nonomura N, Kawana M: Radiological findings of adenolymphoma (Warthin's tumor). *Auris Nasus Larynx* 1997;24:405-9.
- [4] Park J, Inoue S, Ishizuka Y, et al: Salivary gland masses: dynamic MR imaging and pathologic correlation. *Nippon Igaku Hoshasen Gakkai Zasshi* 1997;57:581-5 (Japanese).
- [5] Tsushima Y, Matsumoto M, Endo K: Parotid and parapharyngeal tumours: tissue characterization with dynamic magnetic resonance imaging. *Br J Radiol* 1994;67:342-5..
- [6] Takashima S, Noguchi Y, Okumura T, Aruga H, Kobayashi T: Dynamic MR imaging in the head and neck. *Radiology* 1993;189:813-21
- [7] Asaumi J, Matsuzaki H, Hisatomi M, Konouchi H, Shigehara H, Kishi K: Application of dynamic MRI to differentiating odontogenic myxomas from ameloblastomas. *Eur J Radiol* 2002 ;43:37-41.
- [8] Hisatomi M, Asaumi J, Konouchi H, Yanagi Y, Matsuzaki H, Kishi K: Assessment of ynamic MRI of Warthin's tumors arising as multiple lesions in the parotid glands. *Oral Oncol* 2002;38:369-72.
- [9] Asaumi J, Shigehara H, Konouchi H, Yanagi Y, Hisatomi M, Matsuzaki H, Kishi K: Assessment of carcinoma in the sublingual region based on magnetic resonance imaging. *Oncol Rep* 2002;9:1283-7.
- [10] Konouchi H, Asaumi J, Yanagi Y, Shigehara H, Hisatomi M, Matsuzaki H, Kishi K: Evaluation of tumor proliferation using dynamic contrast enhanced-MRI of oral cavity and oropharyngeal squamous cell carcinoma. *Oral Oncol* 2003;39:290-285.
- [11] Suenaga S, Indo H, Noikura T. Diagnostic value of dynamic magnetic resonance imaging for salivary gland diseases: a preliminary study. *Dentomaxillofac Radiol.* 2001;30:314-8.

Figure legends

Figure 1

CI curves of malignant lymphomas

Thirteen curves of malignant lymphoma (76.5%) reached their maximum CI at 90 ~ 180 s, and the remaining 4 curves (13.5%) reached maximum CIs at 45-60 s. Although the maximum CIs of 5 malignant lymphoma lesions (29.4 %) were above 2.0, 12 curves (70.6%) showed CIs of less than 2.0.

Figure 2

CI curves of SCCs

The time needed to reach maximum CI of the CI curves of 26/30 cases (86.7%) was at 60-105 s and tended to be rapid compared with that of lymphomas. The maximum CIs of 29/30 SCCs (96.7%) were above 2.0.

Figure 3

Relationship between the maximum CI and the time needed to reach the maximum CI
The relationship between maximum CI and time needed to reach the maximum CI is plotted. Of 17 malignant lymphoma lesions in 8 patients, 3 lesions (in 2 patients) could not be differentiated SCC lesions, but the remaining 14 lesions (82.4%) were successfully differentiated SCC lesions on the basis of the line drawn in the Figure.

SCC: closed square, malignant lymphoma: open circle

Figure 1

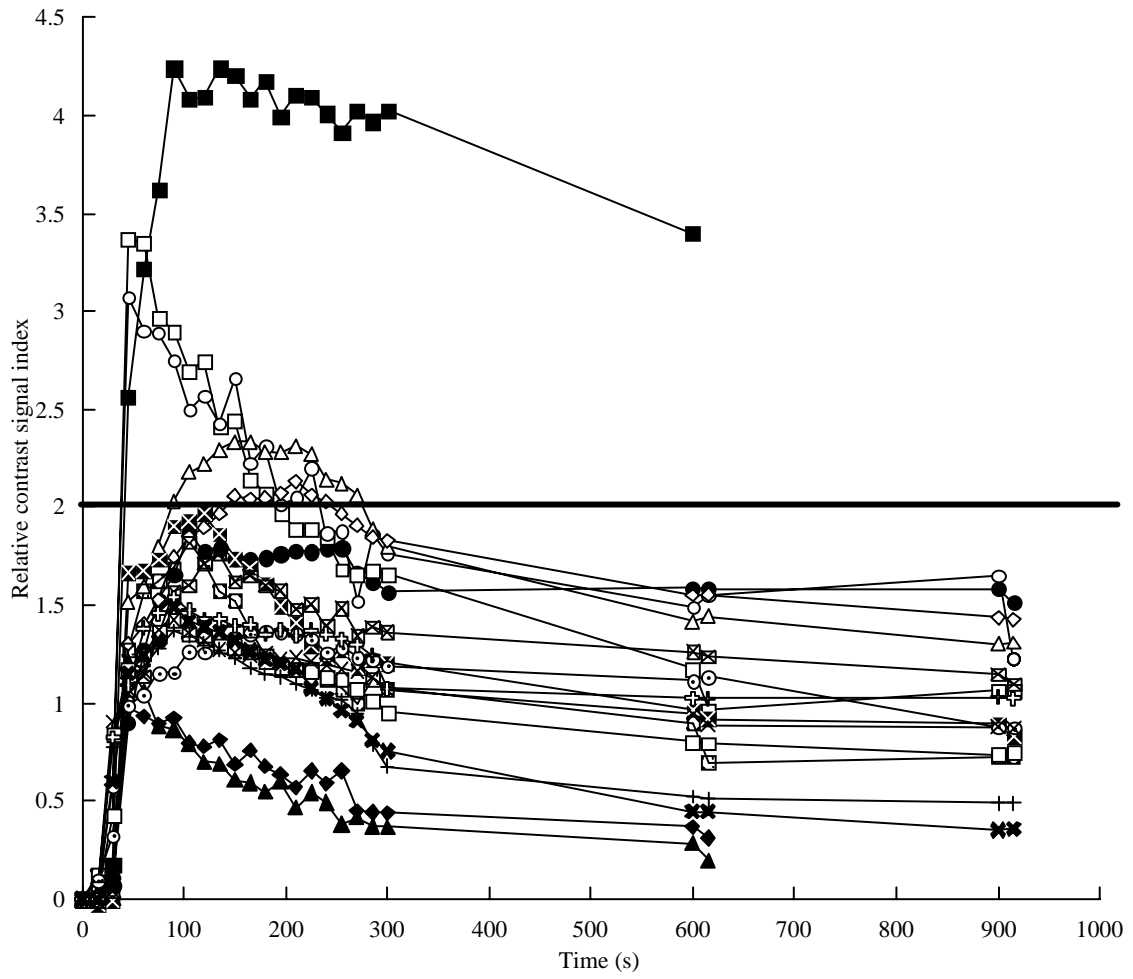


Figure 2

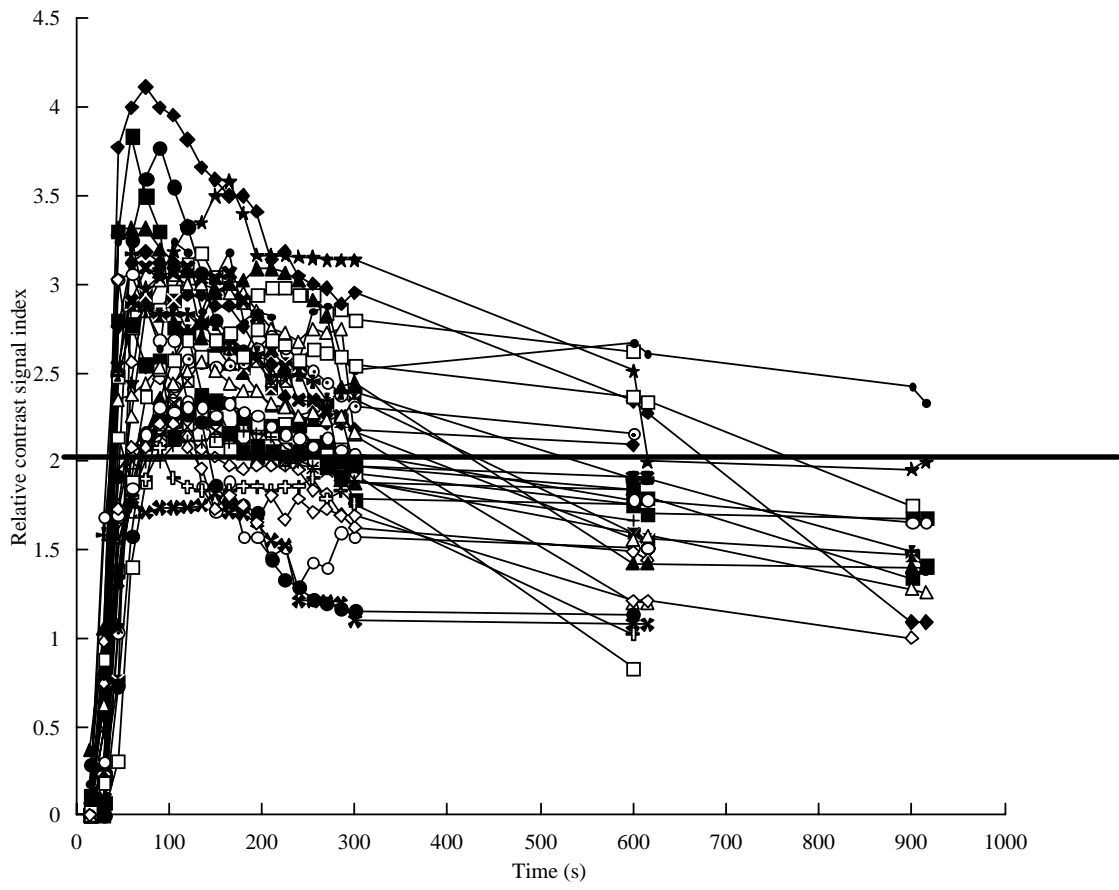
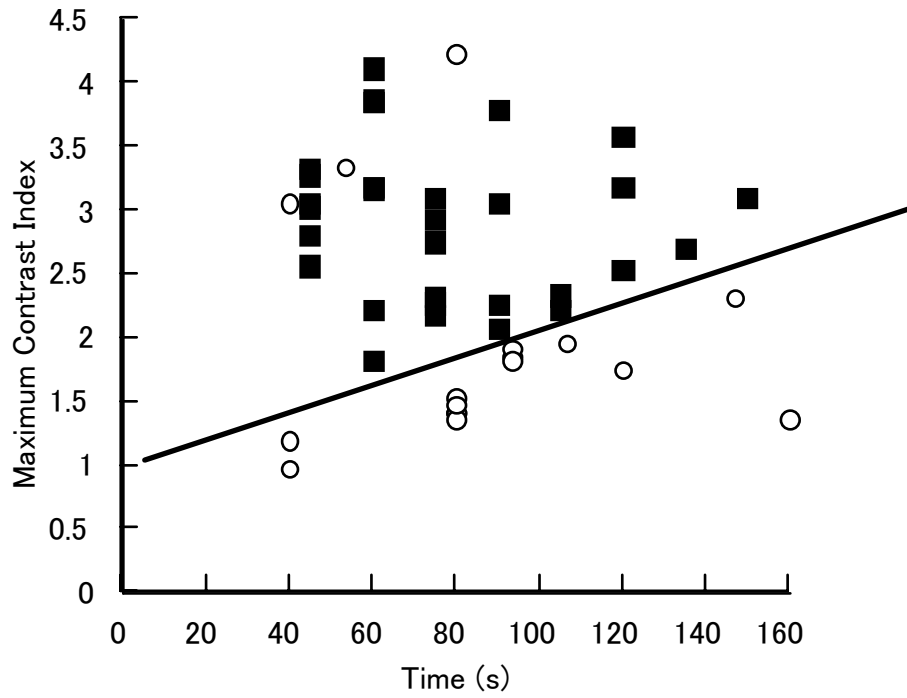


Figure 3



SCC:closed square
Malignant lymphoma:open circle

Table 1 Patient characteristics, maximum CI, time needed to reach the maximum CI in the malignant lymphoma patients

No.	Age (yr)	Sex	Region	Maximum CI	Time for reaching to Maximun CI(s)	THistopathological diagnosis
1(case1)	82	M	Submandibular	1.87	105	B-cell diffuse large cell type
2(case2)	55	M	Submandibular	3.35	60	B-cell diffuse large cell type
3(case2)	55	M	Submandibular	3.07	45	B-cell diffuse large cell type
4(case3)	67	M	Palate	4.24	90	B-cell diffuse large cell type
5(case4)	50	F	Tonsil	0.98	45	Follicular type
6(case4)	50	F	Submandibular	1.21	45	Follicular type
7(case5)	71	M	Buccal	1.97	105	Be-cell low-grade MALT lymphoma
8(case5)	71	M	Buccal	1.93	135	Be-cell low-grade MALT lymphoma
9(case5)	71	M	Orbit	2.33	165	Be-cell low-grade MALT lymphoma
10(case5)	71	M	Orbit	1.97	120	Be-cell low-grade MALT lymphoma
11(case6)	58	M	Buccal	1.37	180	B-cell diffuse large cell type
12(case7)	76	M	Submandibular	1.43	90	B-cell diffuse large cell type
13(case7)	76	M	Submandibular	1.42	90	B-cell diffuse large cell type
14(case7)	76	M	Submandibular	1.37	90	B-cell diffuse large cell type
15(case7)	76	M	Submandibular	1.54	90	B-cell diffuse large cell type
16(case7)	76	M	Submental	1.49	90	B-cell diffuse large cell type
17(case8)	50	M	Submental	1.83	105	Hodgkin Lymphoma
mean \pm SD	66.5 \pm 11.0			1.96 \pm 0.86	97.1 \pm 38.3	

Table 2 Patient characteristics, maximum CI, time needed to reach the maximum CI in the SCC patients

No.	Age (yr)	Sex	Region	Maximum CI	Time for reaching Maximum CI (s)
1	77	F	Cheek	4.11	60
2	64	F	Lower gingiva	3.86	60
3	91	M	Cheek	3.84	60
4	66	M	Lower gingiva	3.78	90
5	80	F	Floor of mouth	3.58	120
6	93	M	Lower gingiva	3.32	45
7	85	M	Tongue	3.27	45
8	72	F	Floor of mouth	3.18	60
9	66	M	Tongue-Pharynx	3.18	120
10	55	M	Upper gingiva	3.17	60
11	70	M	Cheek	3.09	150
12	71	M	Tongue	3.09	75
13	68	F	Upper gingiva	3.06	45
14	74	F	Upper gingiva	3.05	90
15	68	M	Floor of mouth	3.02	45
16	61	F	Lower gingiva	2.94	75
17	70	F	Tongue	2.8	45
18	57	M	Floor of mouth	2.75	75
19	49	F	Tongue	2.69	135
20	47	M	Cheek-Lower gingiva	2.56	45
21	83	F	Lower gingiva	2.53	120
22	58	F	Tongue	2.33	105
23	58	M	Upper gingiva	2.32	75
24	87	M	Lower gingiva	2.27	75
25	64	F	Tongue	2.26	90
26	82	F	Upper gingiva	2.21	60
27	57	M	Tongue	2.21	105
28	61	F	Tongue	2.17	75
29	75	M	Upper gingiva	2.07	90
30	70	M	Tongue	1.82	60
mean \pm SD	69.3 \pm 11.9			2.88 \pm 0.60	78.5 \pm 29.1