

Acta Medica Okayama

Volume 52, Issue 1

1998

Article 11

FEBRUARY 1998

Reconstruction of Bone Defect Using the Bone Transport Technique for a Case of Osteosarcoma of the Femur

Toshifumi Ozaki*

Yoichi Nakatsuka†

Akira Kawai‡

Hirofumi Akazawa**

Toshiyuki Kunisada††

Hajime Inoue‡‡

*Okayama University,

†Okayama University,

‡Okayama University,

**Okayama University,

††Okayama University,

‡‡Okayama University,

Reconstruction of Bone Defect Using the Bone Transport Technique for a Case of Osteosarcoma of the Femur*

Toshifumi Ozaki, Yoichi Nakatsuka, Akira Kawai, Hirofumi Akazawa, Toshiyuki Kunisada, and Hajime Inoue

Abstract

There are few reports on skeletal reconstruction using the bone transport technique to repair bone defects caused by resections of tumors associated with osteosarcoma. We attempted to reconstruct a 23 cm bone defect after resection of an osteosarcoma of the left femur, and succeeded in gaining 17 cm by bone transport. Five years after surgery, this patient remains alive without metastasis or local recurrence.

KEYWORDS: osteosarcoma, bone transport, reconstruction

*PMID: 9548997 [PubMed - indexed for MEDLINE]

Copyright (C) OKAYAMA UNIVERSITY MEDICAL SCHOOL

Brief Note

Reconstruction of Bone Defect Using the Bone Transport Technique for a Case of Osteosarcoma of the Femur

Toshifumi OZAKI*, Yoichi NAKATSUKA, Akira KAWAI, Hirofumi AKAZAWA, Toshiyuki KUNISADA and Hajime INOUE

Department of Orthopaedic Surgery, Okayama University Medical School, Okayama 700-8558, Japan

There are few reports on skeletal reconstruction using the bone transport technique to repair bone defects caused by resections of tumors associated with osteosarcoma. We attempted to reconstruct a 23 cm bone defect after resection of an osteosarcoma of the left femur, and succeeded in gaining 17 cm by bone transport. Five years after surgery, this patient remains alive without metastasis or local recurrence.

Key words: osteosarcoma, bone transport, reconstruction

Bone transport techniques using the Ilizarov apparatus have been used to reconstruct segmental skeletal defects caused by trauma or infection (1-5). However, there have been only a limited number of favorable reports describing skeletal reconstruction by this method after resection of malignant bone tumors (6, 7). We report here a case in which the Ilizarov bone transport technique was used to repair a bone defect left after wide resection of a highly malignant osteosarcoma of the left distal femur of an 11-year-old girl.

Case report. In October 1991, an 11-year-old girl was referred to us for treatment of an osteogenic tumor of the left femur. Upon physical examination, diffuse swelling was noted and the patient complained of pain in the left distal thigh. Swelling had appeared two months earlier and had gradually increased in size. General examination did not reveal any other abnormalities. However, a simple radiograph disclosed abnormal sclerotic change and periosteal reaction on the distal femoral shaft (Fig. 1). Chest radiograph did not show any metastatic pulmonary lesions. Computed tomography

(CT) and magnetic resonance (MR) imaging demonstrated extraskeletal invasion of the tumor from the left distal femur. Bone scan revealed a "hot spot" on the left distal

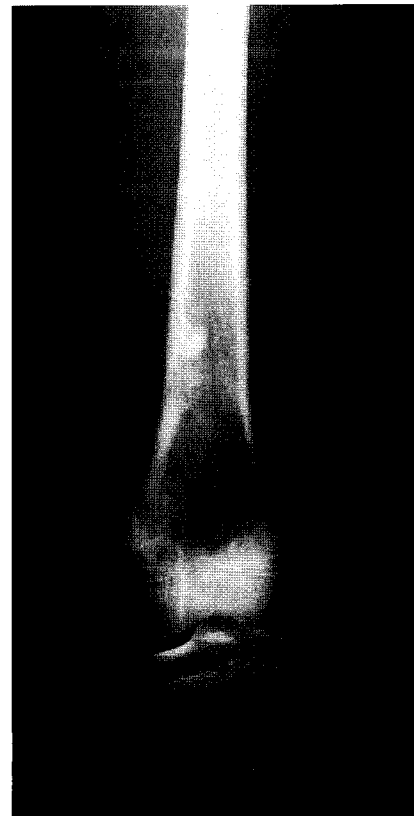


Fig. 1 Radiograph showing abnormal sclerotic change and periosteal reaction at the distal end of the femoral shaft upon the initial presentation.

* To whom correspondence should be addressed.




Fig. 2 (Left) Photomicrograph of the biopsy specimen, showing obviously malignant pleomorphic and bizarre tumor cells. The osteoid is diffusely noted ($\times 400$).

Fig. 3 (Right) Radiograph showing fragile callus formation on the distraction sites four months after the beginning of bone transport.

femur. A bone tumor with hyper vascularity was identified by digital subtraction angiography (DSA). A biopsy specimen showed pleomorphic and bizarre tumor cells with osteoid formation (Fig. 2). Based on these findings, a diagnosis of osteosarcoma (stage IIB) (8) was made.

Immediately after diagnosis, preoperative chemotherapy including high-dose methotrexate (300 mg/kg), doxorubicin (60 mg/m²) and cisplatin (120 mg/m²) was started and continued for three months. Radiological evaluation indicated that preoperative chemotherapy was very effective. After preoperative chemotherapy, the distal half of the femur and the proximal end of the tibia including the knee joint and surrounding muscles were excised leaving a wide margin, resulting in a 23 cm bone defect. Upon

histological examination of the resected specimens, no viable tumor cells were observed. Two weeks after surgical intervention, bone transportation was applied to the remaining segments of the femur and tibia at rates of 0.5 and 1 mm/day, respectively (Fig. 3). Since osteoformation at the distraction sites was poor during the period of adjuvant chemotherapy, distant bone transport was suspended for about 100 days. The gap was finally closed by docking of the two ends eight months after the initial surgery. Eleven months after docking, adequate union at the docking site and consolidation of the elongated regions were confirmed by serial radiographs. The final examination performed 5 years after surgery at the age of 16 revealed that bone transportation measuring 17 cm in

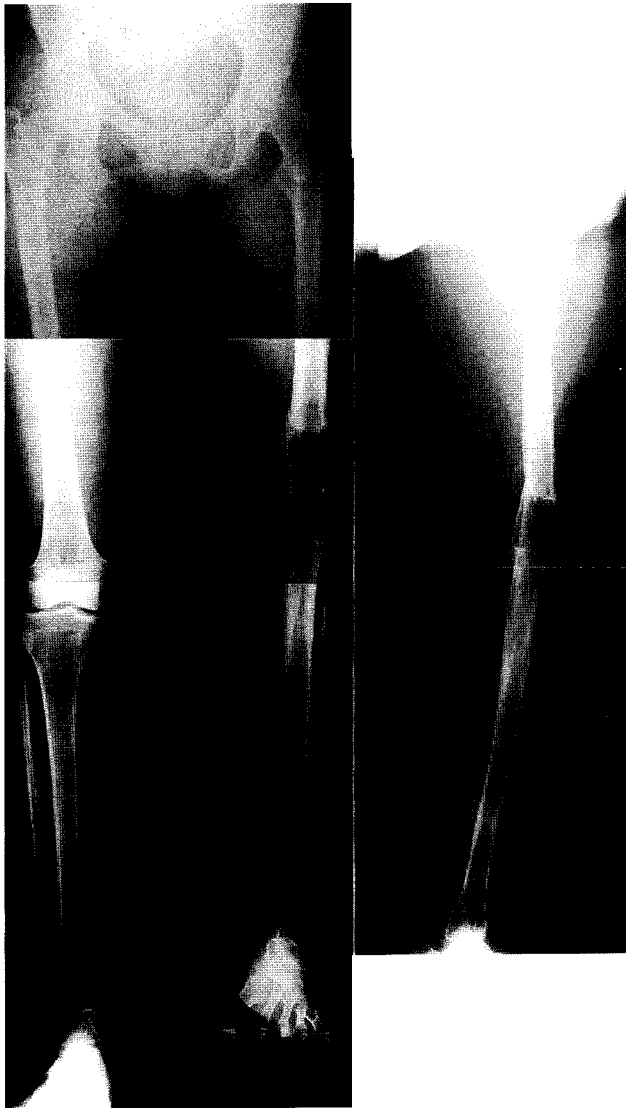

Fig. 4 Anteroposterior and lateral radiographs taken two months after removal of the apparatus, showing sufficient union of the docking and elongated sites.

length had been maintained (Fig. 4). The discrepancy in leg lengths is currently corrected by a thick-heeled shoe. Clinical and radiological examinations revealed neither local recurrence nor distant metastasis. The patient can walk by herself without support.

Discussion

Advances in adjuvant chemotherapy have permitted limb salvage in many patients with primary malignant bone tumors. Wide or *en bloc* resection with or without

reconstruction is the treatment of choice. Since bone allograft is difficult in Japan, the defect must be reconstructed using autologous grafts or a prosthetic replacement. However, if the defect is fairly long, autologous grafting is unlikely to be successful. Artificial materials for reconstruction of bony defects also involve several problems, such as infection, prosthetic loosening, and breakage. The bone transport method solves these problems because the gap is filled with *de novo* autogenous bone.

To our knowledge, there have only been a few papers describing bone transport for reconstruction of defects caused by resection of osteogenic sarcomas. Stoffelen *et al.* (6) reported a case of periosteal osteosarcoma of the ulna, and Tsuchiya *et al.* (7) reported two cases involving the proximal and middle part of the tibiae, respectively. These authors stressed that the bone transport method was very useful for reconstruction after resection of osteogenic sarcomas. Several papers have described bone formation in association with the administration of anti-cancer agents. Prevot *et al.* (9) studied distraction osteogenesis using an Ilizarov fixator in an animal subjected to prolonged chemotherapy (methotrexate and doxorubicin), and found that the chemotherapy decreased osteogenesis activity but did not totally. Jarka *et al.* (10) also reported on distraction osteogenesis during administration of high dosages of methotrexate in a rabbit model, and indicated that there were no significant differences between the methotrexate-treated group and the control when examined histologically and radiographically. During adjuvant chemotherapy after tumor resection in our patient, osteogenesis at the distraction sites was inhibited, so distant bone transport was suspended for about 100 days. Nevertheless, a gain of 17 cm was finally obtained by double segmental transport. The Ilizarov apparatus was attached for 19 months.

We feel that the Ilizarov bone transport method offers new possibilities for reconstruction of bones after resection of bone sarcomas.

References

1. Catagni M: Classification and treatment of nonunion; in Operative Principles of Ilizarov, Bianchi Maiocchi A and Aronson J eds, Williams and Wilkins, Baltimore (1991) pp190-198.
2. Cattaneo R, Catagni M and Johnson EE: The treatment of infected nonunion and segmental defects of the tibia by the methods of Ilizarov. *Clin Orthop Surg* (1982) **280**, 143-152.
3. Green SA, Jackson JM, Wall DM, Marinow H and Ishkhanian J: Man-

- agement of segmental defects by the Ilizarov intercalary bone transport method. *Clin Orthop Relat Res* (1992) **280**, 136-142.
4. Ilizarov GA and Lediaev, VI: Replacement of defects of long tubular bones by means of one of their fragments. *Vesten Khir IM pl Grekova* (1969) **102**, 77-84 (in Russian).
 5. Ilizarov GA: Transosseous osteosynthesis; in *Theoretical and Clinical Aspects of the Regeneration and Growth Tissue*, Springer-Verlag, Berlin (1992) pp453-543.
 6. Stoffelen D, Lammens J and Fabrey G: Resection of a periosteal osteosarcoma and reconstruction using the Ilizarov technique of segmental transport. *J Hand Surg* (1993) **18B**, 144-146.
 7. Tsuchiya H, Tomita K, Tsubota S, Shinokawa Y, Katsuo S and Tokuumi Y: Treatment of bone and soft tissue tumors using external fixators; in *Limb Salvage, Current Trends. Proceedings of the 7th International Symposium of Limb Salvage*, Tan SK ed, Singapore (1993) pp137-143.
 8. Enneking WF: A system of staging musculoskeletal neoplasms. *Clin Orthop Surg* (1986) **204**, 9-24.
 9. Prevot J, Poncelet T, Lemelle JL, Lascombes P, Blanquart D, Membre H and Ollive D: Etude de l'ostéogenèse en distraction sur un organisme animal soumis à une chimiothérapie anti-cancéreuse. *Chir Pediatr* (1988) **29**, 226-230.
 10. Jarka D, Nicholas R and Aronson J: Successful distraction osteogenesis in the presence of high dose methotrexate, a rabbit model; in *Limb Salvage, Current Trends, Proceedings of the 7th International Symposium of Limb Salvage*, Tan SK ed, Singapore (1993) p508.

Received July 22, 1997; accepted October 13, 1997.