

Acta Medica Okayama

Volume 60, Issue 3

2006

Article 1

JUNE 2006

Decreased levels of insulin-like growth factor-1 and vascular endothelial growth factor relevant to the ossification disturbance in femoral heads spontaneous hypertensive rats.

Takamitsu Komiyama, *Okayama University*

Keiichiro Nishida, *Okayama University*

Masanori Yorimitsu, *Okayama University*

Hideyuki Doi, *Okayama University*

Shinichi Miyazawa, *Okayama University*

Ai Kitamura, *Okayama University*

Aki Yoshida, *Okayama University*

Yoshihisa Nasu, *Okayama University*

Nobuhiro Abe, *Okayama University*

Toshifumi Ozaki, *Okayama University*

Decreased levels of insulin-like growth factor-1 and vascular endothelial growth factor relevant to the ossification disturbance in femoral heads spontaneous hypertensive rats.*

Takamitsu Komiyama, Keiichiro Nishida, Masanori Yorimitsu, Hideyuki Doi, Shinichi Miyazawa, Ai Kitamura, Aki Yoshida, Yoshihisa Nasu, Nobuhiro Abe, and Toshifumi Ozaki

Abstract

Ossification disturbance in femoral head reportedly is seen in the Spontaneously Hypertensive rats (SHR) between ages of 10 and 20 weeks. We investigated serum and tissue levels of insulin-like growth factor-1 (IGF-1) and vascular endothelial growth factor (VEGF) in SHR relevant to the ossification disturbance and osteonecrosis of the femoral head. Serum levels of IGF-1 and VEGF were significantly lower in SHR than in Wistar Kyoto rats (WKY) at weeks 5, 10, 15 and 20 ($p < 0.005$). The incidence of histological ossification disturbance of the femoral head was higher in SHR (59%) than in WKY (40%) at week 20. Lower serum and local levels of VEGF in SHR appeared to be related to the incomplete ossification of the femoral heads. Immunohistochemical study showed significantly lower numbers of IGF-1 and VEGF positive chondrocytes in the femoral epiphyseal cartilage of SHR than in those of WKY at weeks 10, 15 and 20. Our results suggest that local and/or systemic levels of IGF-1 and VEGF between ages of 5 and 20 weeks might play roles in the pathogenesis of ossification disturbance of the femoral head in SHR.

KEYWORDS: spontaneous hypertensive rats, insulin like growth factor-1, vascular endothelial growth factor, ossification disturbance, osteonecrosis

*PMID: 16838042 [PubMed - indexed for MEDLINE]

Copyright (C) OKAYAMA UNIVERSITY MEDICAL SCHOOL

Original Article

Decreased Levels of Insulin-like Growth Factor-1 and Vascular Endothelial Growth Factor Relevant to the Ossification Disturbance in Femoral Heads Spontaneous Hypertensive Rats

Takamitsu Komiyama^a, Keiichiro Nishida^{a,b*}, Masanori Yorimitsu^a, Hideyuki Doi^a, Shinichi Miyazawa^a, Ai Kitamura^a, Aki Yoshida^a, Yoshihisa Nasu^a, Nobuhiro Abe^a, and Toshifumi Ozaki^a

Departments of ^aOrthopaedic Surgery, and ^bHuman Morphology, Okayama University Graduate School of Medicine, Dentistry and Pharmaceutical Sciences, Okayama 700-8558, Japan

Ossification disturbance in femoral head reportedly is seen in the Spontaneously Hypertensive rats (SHR) between ages of 10 and 20 weeks. We investigated serum and tissue levels of insulin-like growth factor-1 (IGF-1) and vascular endothelial growth factor (VEGF) in SHR relevant to the ossification disturbance and osteonecrosis of the femoral head. Serum levels of IGF-1 and VEGF were significantly lower in SHR than in Wistar Kyoto rats (WKY) at weeks 5, 10, 15 and 20 ($p < 0.005$). The incidence of histological ossification disturbance of the femoral head was higher in SHR (59%) than in WKY (40%) at week 20. Lower serum and local levels of VEGF in SHR appeared to be related to the incomplete ossification of the femoral heads. Immunohistochemical study showed significantly lower numbers of IGF-1 and VEGF positive chondrocytes in the femoral epiphyseal cartilage of SHR than in those of WKY at weeks 10, 15 and 20. Our results suggest that local and/or systemic levels of IGF-1 and VEGF between ages of 5 and 20 weeks might play roles in the pathogenesis of ossification disturbance of the femoral head in SHR.

Key words: spontaneous hypertensive rats, insulin like growth factor-1, vascular endothelial growth factor, ossification disturbance, osteonecrosis

Legg-Calve-Perthes' disease (LCPD) is characterized by ossification disturbance and subsequent osteonecrosis of the femoral head. The reported incidence of LCPD is approximately 1: 9,000 children (1: 8,000 boys and 1: 30,000 girls) and 80% of the cases are found between the ages of 4 and 9 years [1-6]. If LCPD is untreated or not treated appropriately, ossification disturbance develops flattening of the femoral head due to osteonecro-

sis, which can leave a deformity that result in osteoarthritis of the hip in adult life. Although the prognosis is clear, the pathogenesis of LCPD is still uncertain.

The spontaneously hypertensive rats (SHR) is widely used as an animal model for hypertension. SHR exhibit a variety of hormonal imbalances, including prolactin, follicle-stimulating hormone, testosterone [7-9], and parathyroid hormone [10], which are known to influence the process of chondrogenesis and bone remodeling. It is also known that the SHR exhibits osteonecrosis of the femoral head between the ages of 10 and 20 weeks, the period

Received August 9, 2005; accepted November 30, 2005.

*Corresponding author. Phone: +81-86-235-7273; Fax: +81-86-223-9727
E-mail: knishida@md.okayama-u.ac.jp (K. Nishida)

preceding skeletal maturity. Although the mechanism of osteonecrosis seen in SHR remains unclear, SHR is accepted for the animal model of human LCPD because radiographic appearances of the femoral heads of SHR resemble those of LCPD [11–13]. Recent radiographic and histological analyses demonstrated that the osteonecrosis in SHR is preceded by a disturbance of the cartilage mineralization and ossification, despite normal hypertrophy of the epiphyseal cartilage, suggesting that abnormal development of the femoral epiphysis occurs much earlier than the osteonecrosis [14–16]. Recent report suggested that the occlusion of the epiphyseal vessels during the process of enchondral ossification might induce the ischemic necrosis of the femoral head, which might lead to the breakdown of the vulnerable immature epiphysis in SHR by the mechanical forces [16].

Two of the known factors required for enchondral ossification are insulin-like growth factor (IGF-1) and vascular endothelial growth factor (VEGF). IGF-1 is an essential factor for cell function and differentiation of chondrocytes during enchondral ossification [17]. Neidel *et al.* reported persistent, low serum levels of IGF-1 in prepubertal children with LCPD [18]. More recently, Kikkawa *et al.* reported that peak expression of IGF-1 in epiphyseal chondrocytes in SHR is delayed when compared with Wistar Kyoto rats (WKY) during the ages of 1 to 6 weeks [14]. Although the precise relationship is unclear in chondrocytes, IGF-1 is known to regulate production of VEGF in other cell types [8, 19–22]. VEGF is responsible for hypertrophic cartilage neovascularization through a paracrine release by chondrocytes, and promotes the invasion of endothelial cells into the cartilaginous tissue [23]. In the current study, we used SHR, and the closely related WKY, which do not develop spontaneous osteonecrosis of the femoral head. We hypothesized that if the inhibition of vascular invasion into the epiphyseal cartilage and ossification disturbance of the SHR femoral head are related to the low serum or low tissue levels of IGF-1 and VEGF, then the levels of both factors should be different in the 2 types of rats during the developmental period preceding skeletal maturity.

Materials and Methods

Animals. SHR were originally raised by selective inbreeding of WKY. We used SHR (n=40) (Charles River Inc., Yokohama, Japan) as the disease models of epiphyseal ossification disturbance of cartilage, and WKY (n=20) (Charles River Inc., Yokohama, Japan) as normal control animals. All animals were used in accordance with the Policies and Guidelines for Care and Use of Laboratory Animals of Okayama University, and all efforts were made to minimize animal suffering. The rats were euthanized by systemic perfusion of a mixture of 2% paraformaldehyde and 2% glutaraldehyde in 0.1 M phosphate-buffered saline (PBS) under general anesthesia at weeks 5, 10, 15 and 20 (SHR: each 10, WKY: each 5), and the serum samples were taken and stored at -80°C until analysis.

Radiographic study. The femoral head samples were perfusion-fixed with a mixture of 2% paraformaldehyde and 2% glutaraldehyde in 0.1 M PBS. The radiographs of excised samples were taken by Softex CNB-2 (MFG and EXP, Softex Co. Ltd., Tokyo, Japan; 52 kV, 40 mA, exposure time 10 s). All the radiographic analyses were carried out on printed pictures magnified at $\times 100$. In the current study, the radiographic appearances of the femoral heads were divided into 3 types; Round (no sign of deformation or fracture), Flat (deformation of femoral head without bone fracture), and Crushed (deformation and bone fracture of femoral head) (Fig. 1).

Measurement of IGF-1 and VEGF concentrations in the serum samples. Serum samples were taken from both WKY and SHR at weeks 5, 10, 15 and 20. The concentration of VEGF was measured by ELISA (Quantikine Mouse VEGF ELISA Kit, R&D systems Inc., Minneapolis, MN, USA), and IGF-1 by radioimmunoassay (Rat IGF-1 Radioimmunoassay Kit, Diagnostic Systems Laboratories Inc., Webster, TX, USA). The serum levels of IGF-1 and VEGF in SHR at each stage were analyzed separately to further examine the difference between histological stages, and the correlation with ossification of the femoral heads.

Histological examination. Samples were decalcified in 4% ethylene diamine tetra-acetic acid (EDTA) and 10% sucrose in cacodylate buffer (pH

7.3) for 7–10 days. The coronal araffin sections ($4.5 \mu\text{m}$) were stained by hematoxylin and eosin. Histological appearances of the femoral heads were scored from 0 to 2, according to the area of ossification; Stage 0: ossification of less than $1/3$ of the femoral head, Stage 1: ossification from $1/3$ to $2/3$ of the femoral head, Stage 2: ossification of $2/3$ or more of the femoral head (Fig. 2). Blinded assessments of histological and radiographic data were made independently by 2 of the authors (TK and KN). Differences in opinions were resolved by consensus.

Immunohistochemistry. The paraffin sections were incubated with 0.3% H_2O_2 that diluted with PBS for 30 min at room temperature to inactivate endogenous peroxidase. Each section was treated with PBS containing 2% BSA for 30 min at room temperature to block non-specific binding to sections and eliminate non-specific staining. The slides were then incubated with rabbit polyclonal

anti-IGF-1 ($5 \mu\text{g}/\text{ml}$) or goat polyclonal anti-VEGF ($5 \mu\text{g}/\text{ml}$) (Santa Cruz Biotechnology, Santa Cruz, CA, USA) at 4°C overnight, and incubated for 30 min at room temperature with the secondary antibody (DAKO LSAB Kit, DAKO, Kyoto, Japan). After 3 washings by PBS, the sections were immersed in 0.1% 3,3'-diaminobenzidine tetrahydrochloride (DAB) and 1% hydrogen peroxide. The sections were then counterstained with methylgreen, and observed by light microscopy.

Quantitative analysis for IGF-1 and VEGF positive cells.

The population of IGF-1 and VEGF positive chondrocytes within the femoral heads was examined in SHR ($n=10$) and WKY ($n=5$) at weeks 10, 15 and 20. The positive-cell numbers were counted within the 3 defined square areas (medial, central, lateral, $20 \times 20 \mu\text{m}$) of Stage 0 and 1 femoral epiphyseal cartilage of the rats at weeks 10, 15 (SHR; $n=10$, WKY; $n=10$) and 20

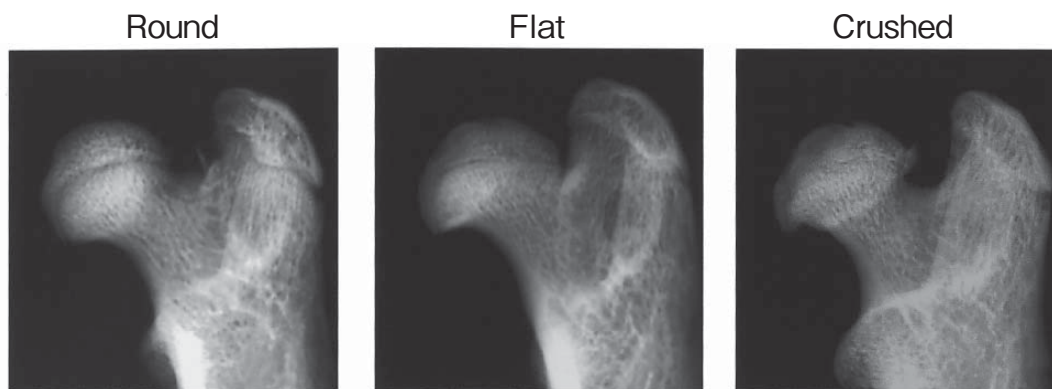


Fig. 1 Radiographic appearances of the femoral heads of SHR (Softex). Femoral heads were divided into 3 types: Round, Flat, Crushed.

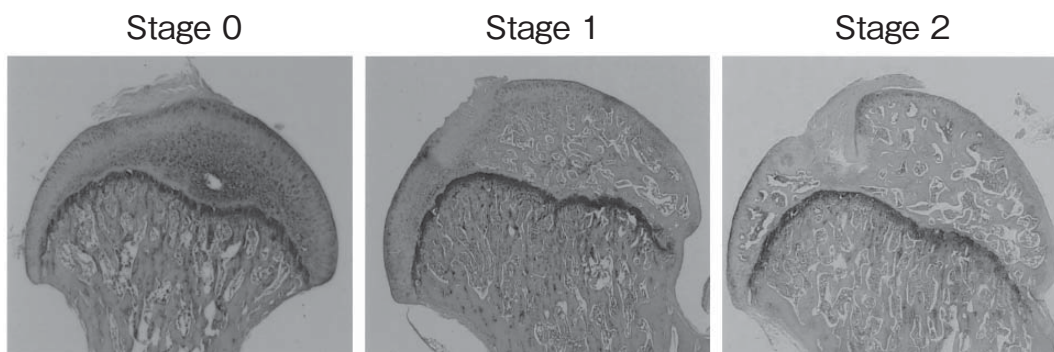


Fig. 2 Histology of the epiphysis of femoral head of SHR (HE stain). Femoral heads were classified into the following 3 stages according to the pathological findings. Stage 0, ossification less than $1/3$ of femoral head; Stage 1, ossification from $1/3$ to $2/3$ of the femoral head; Stage 2, ossification more $2/3$ of the femoral head (original magnification $\times 10$).

(SHR; n=10, WKY; n=4), and averaged. There was no difference in ossification pattern in the femoral heads between SHR and WKY at week 5.

Statistical analysis. The serum levels of IGF-1 and VEGF were expressed as mean \pm SD. Differences between WKY and SHR were statistically analyzed by Mann-Whitney U test or by Student's *t*-test appropriately using Macintosh StatView version 6 (SAS Institute Inc., Cary, NC, USA).

Results

Radiological study. The radiographic morphology of the femoral heads of WKY was Round throughout the study, except for one femoral head (10%) at week 20, which showed a Flat appearance. In contrast, Flat femoral heads were seen in 40% and in 60% of SHR at weeks 10 and 15, respectively. Femoral heads with a Crushed appearance were seen in 5% and in 15% of SHR at weeks 15 and 20, respectively (Table 1).

Serum levels of IGF-1 and VEGF. Serum levels of IGF-1 were significantly lower in SHR than

in WKY at weeks 5, 10 and 15. There was no significant difference in serum levels of IGF-1 between 2 lines of rats at week 20. The serum levels of VEGF were significantly lower in SHR than in WKY at each measurement point ($p<0.005$) (Table 2). Analysis by ELISA showed the serum levels of IGF-1 were not significantly different among the stages at weeks 10 and 20. Although the serum levels of IGF-1 associated with Stage 1 and 2 cartilage were significantly lower than those of Stage 0 in SHR at week 15 ($p<0.01$, $p<0.05$, respectively) (Fig. 3), the levels were much lower than those with WKY at the same age. The serum levels of VEGF were not significantly different among the stages in SHR at week 10. However, at week 15, the serum levels of VEGF in SHR with Stage 0 and 1 femoral heads were significantly lower than those with Stage 2 ($p<0.05$ and $p<0.005$, respectively). At week 20, the serum levels of VEGF of Stage 0 were significantly lower than those of Stages 1 and 2 in SHR ($p<0.005$) (Fig. 3).

Histology. The number of femoral heads in each stage of ossification was summarized in Table 3. The femoral heads of SHR at week 5 and WKY at weeks 5, 10 and 15 showed no ossification (Stage 0). At week 10, Stage 0 ossification was seen in 8 of 20 femoral heads (40%), and Stage 1 ossification was seen in 4 of 20 femoral heads (20%) of SHR. Two of the latter had osteonecrosis with empty lacunae. Stage 2 ossification was seen in 8 of 20 femoral heads (40%) of SHR, 2 of which had osteonecrosis. At week 15, all 3 stages of ossification of the femoral head were seen: Stage 0 in 4 (21.1%),

Table 1 Number of femoral heads in each radiographic type

	10 weeks		15 weeks		20 weeks	
	SHR	WKY	SHR	WKY	SHR	WKY
Round	12	10	7	10	7	9
Flat	8	0	12	0	10	1
Crushed	0	0	1	0	3	0
Total	20	10	20	10	20	10

Table 2 Serum levels of IGF-1 and VEGF
IGF-1 (ng/ml)

	5 weeks	10 weeks	15 weeks	20 weeks
SHR (n=40)	633.8 \pm 86.2	1082.9 \pm 152.3	1115.0 \pm 154.0	988.9 \pm 106.9
WKY (n=20)	1156.4 \pm 127.9*	1586.0 \pm 231.5*	1414.0 \pm 227.9*	1164.4 \pm 206.5

(* $p<0.005$)

VEGF (pg/ml)	5 weeks	10 weeks	15 weeks	20 weeks
SHR (n=40)	61.7 \pm 30.6	58.2 \pm 2.5	58.9 \pm 4.5	59.2 \pm 3.8
WKY (n=20)	67.1 \pm 6.1*	71.9 \pm 5.3*	72.7 \pm 4.4*	73.4 \pm 5.6*

(* $p<0.005$)

Table 3 Number of femoral heads in each stage of ossification

	5 weeks		10 weeks		15 weeks		20 weeks	
	SHR	WKY	SHR	WKY	SHR	WKY	SHR	WKY
Stage 0	20	10	8	10	4	10	4(2)	0
Stage 1	0	0	4(2)	0	6	0	6(5)	4
Stage 2	0	0	8(2)	0	9(7)	0	7(5)	6
Total	20	10	20	10	19	10	17	10

(): Osteonecrosis

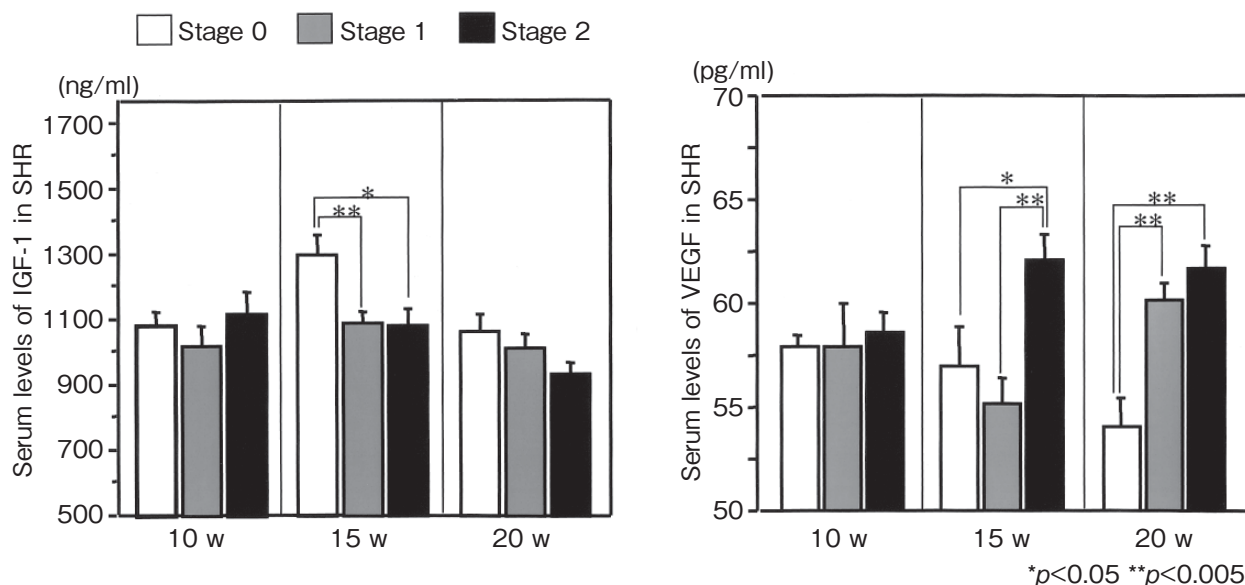


Fig. 3 Serum levels of IGF-1 and VEGF in each ossification stage at weeks 10, 15 and 20 in SHR. At week 15, serum levels of IGF-1 of Stage 0 were significantly higher than those of Stages 1 and 2. Serum levels of IGF-1 were not significantly different among the stage at weeks 10 and 20. Serum levels of VEGF were not significantly different among the stages at week 10. At week 15, serum levels of VEGF of Stage 2 were significantly higher than those of Stages 0 and 1. At week 20, serum levels of VEGF of Stage 0 were significantly lower than those of Stages 1 and 2.

Stage 1 in 6 (31.6%), and Stage 2 in 9 (47.4%) of 19 SHR femoral heads. Seven of 9 Stage 2 SHR femoral heads (77.8%) showed osteonecrosis. At week 20, the incidence of Stage 1 and 2 ossification of the WKY femoralheads (10 of 10, 100%) was higher than those in SHR (13 of 17 heads; 76.4%) and 12 of 17 femoral heads (70.6%) of SHR was showed osteonecrosis. Extensive crushing precluded further histological analysis of 4 of the SHR femoral heads at weeks 15 (1 head) and (3 heads).

Immunohistochemistry. The local expression of IGF-1 showed a significant and transient increase at week 15 followed by a decrease at week 20 in SHR and WKY. The populations of IGF-1 positive

chondrocytes in the femoral heads of WKY were $50.8 \pm 20.5\%$, $87.5 \pm 5.2\%$, and $7.0 \pm 16.9\%$ at weeks 10, 15, and 20, respectively. The positive reactions for IGF-1 were significantly lower in hypertrophic chondrocytes in the femoral heads of SHR at weeks 10, 15 and 20 ($p < 0.001$) (Fig. 4). The populations of VEGF positive chondrocytes were significantly lower than those in WKY throughout the experimental period (Fig. 5).

Discussion

The histological analysis of the current study showed that osteonecrosis was found in 4 of 20 and 7

of 19 SHR femoral heads at weeks 10 and 15, respectively despite the higher incidence of ossification (Stage 1 and 2) in SHR than WKY at the same time points. At week 20, WKY showed Stage 1 or 2 ossifications in 13 of 17 femoral heads, however, osteonecrosis was seen in only 71.1% (12 of 17) of them. These findings agree with those of Sibahara *et al.* who reported that the ossification disturbance and osteonecrosis of femoral heads in SHR are frequently seen between ages of 10 and 20 weeks [16]. These results suggested that the period between weeks 5 and 20 might be crucial for the investigation for the causation of the ossification disturbance, incomplete ossification and osteonecrosis seen in SHR.

Several studies have reported delayed expression of the serum levels of IGF-1 during the development of SHR [14, 24, 25]. Neidel *et al.* reported that serum levels of IGF-1 were lower in LCPD than in the control group, and this decrease was confined to the first 2 years of the disease and followed by a non-

significant rebound [18]. Our results of current study showed that the serum levels of IGF-1 were significantly lower in SHR than in WKY at weeks 5, 10 and 15, but not at week 20. As IGF-1 is known to promote the proliferation of osteoblasts, and stimulates the activation of IGF receptor, Ras, ERK1/2 and Akt in osteoprogenitor cells [26], low level of serum IGF-1 seen in SHR might induce the early incomplete ossification. Immunohistochemical study demonstrated that local expression levels of IGF-1 by chondrocytes of SHR were significantly lower than those of WKY. The increase in the number of IGF-1 positive cells at weeks 15 might promote the terminal differentiation of chondrocytes toward ossification. The relatively low level of IGF-1 in SHR might be insufficient to promote chondrocyte differentiation, which could lead to ossification disturbance. The serum levels of IGF-1 of SHR did not relate to the histological appearance of femoral heads at weeks 10 and 20. However, the levels were significantly lower in SHR femoral heads of Stages 1 and 2 at

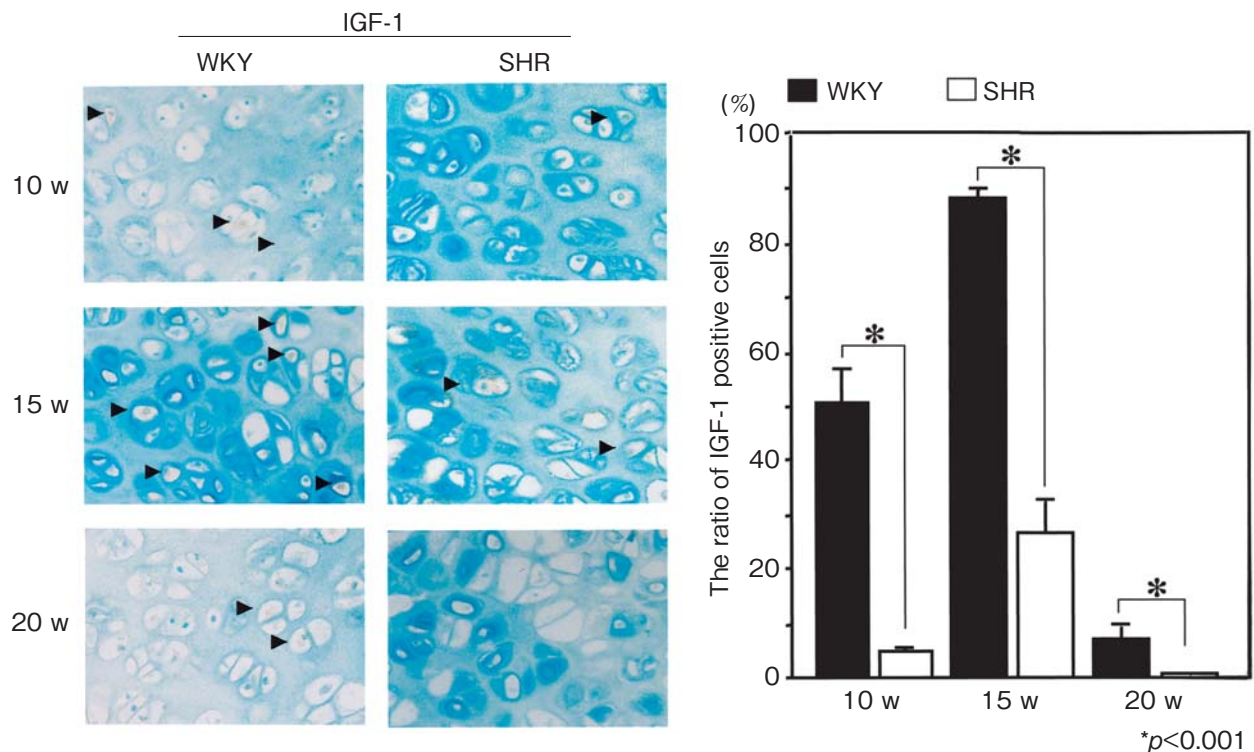


Fig. 4 Immunohistochemical staining for IGF-1 on paraffin embedded hypertrophic chondrocytes in the epiphysis of femoral heads at weeks 10, 15 and 20 (original magnification 200 \times). The number of hypertrophic chondrocytes with positive for IGF-1 tended to increase in both groups of rats at weeks 10 and 15. However at week 20, the numbers decreased significantly. The ratio of the positive cells for IGF-1 in SHR was significantly lower in WKY at weeks 10, 15 and 20. The arrow is positive cell for IGF-1.

week 15 (Fig. 4). The reason of this transient increase of serum IGF-1 is unclear, but it might explain the dissimilar findings in serum levels of IGF-1 in LCPD in the previous studies [27, 28].

VEGF is expressed by hypertrophic chondrocytes and promotes the ossification by angiogenesis [24]. In the current study, serum VEGF level was lower in SHR with Stage 0 or 1 femoral heads than those with Stage 2 at weeks 15, and lower in SHR with Stage 0 femoral heads than those with Stage 1 or 2 at weeks 20 (Fig. 4). These results suggest that low level of serum VEGF might be related to the incomplete ossification. Kim *et al.* reported that VEGF expression was increased in ischemic piglet femoral heads, and its spatial expression was altered in the epiphyseal cartilage after ischemic necrosis of the immature femoral head [25].

Our results suspected that osteonecrosis of incomplete ossification femoral head in SHR was lead by lower serum and local levels of IGF-1 and VEGF, and that a condition of lower serum and local levels

of IGF-1 and VEGF could not preserve adequate bone metabolism in femoral head. IGF-1 and VEGF are known to be essential coordinators of chondrocyte differentiation and ossification, chondroblast function, angiogenesis and bone formation in femoral heads. The regulatory mechanism of serum levels of IGF-1 and VEGF in SHR is still unknown. The relationship between IGF-1 and VEGF has been reported with various cells, in the endothelial cells or carcinoma cells, IGF-1 promotes the expression of VEGF, which is an essential growth factor involved in neovascularization, vascular invasion, and activation of osteoprogenitor cells [8, 19–21]. In retinal cells, IGF-1 has been shown to act synergistically with VEGF to increase angiogenesis [22]. Whilst clarification of the regulation of IGF-1 and VEGF in chondrocytes is needed, the current study was not designed to show causation and did not attempt to show the strength of the relationship between IGF-1 and VEGF. In the current study, serum levels of the 2 factors did not appear to relate to the stages of

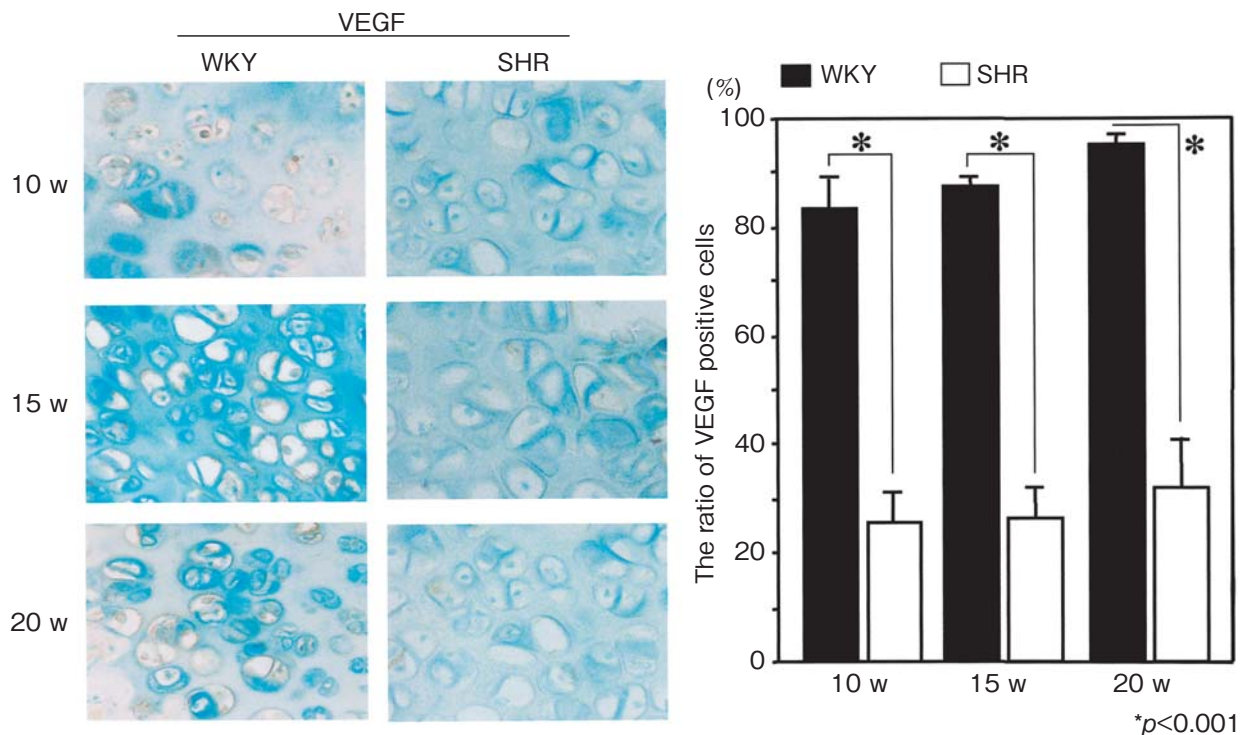


Fig. 5 Immunohistochemical staining for VEGF on paraffin embedded hypertrophic chondrocytes in the epiphysis of femoral heads at weeks 10, 15 and 20 (original magnification 200 \times). The number of hypertrophic chondrocytes positive for VEGF tended to increase in both rats at weeks 10, 15 and 20. The ratio of the positive cells for VEGF in SHR was significantly lower in WKY at weeks 10, 15 and 20.

ossification in a consistently parallel manner. However, the results of immunohistochemistry indicated that local expression of IGF-1, as well as VEGF in hypertrophic chondrocytes of SHR femoral head were significantly lower than those in WKY (Fig. 4, 5).

Acknowledgments. The authors thank C. McCown for assistance in editing the manuscript. We also thank Prof. A. Ohtsuka (Department of Human Morphology, Okayama University Graduate School of Medicine, Dentistry and Pharmaceutical Sciences), T. Sato (Okayama University Hospital) and T. Kikuchi (Department of Orthopaedic Surgery, Okayama University Graduate School of Medicine, Dentistry and Pharmaceutical Sciences).

References

- Barker DJ, Dixon E and Taylor JF: Perthes' disease of the hip in three regions of England. *J Bone Joint Surg Br* (1978) 60: 478-480.
- Hall AJ, Barker DJ, Dangerfield PH and Taylor JF: Perthes' disease of the hip in Liverpool. *Br Med J (Clin Res Ed)* (1983) 10: 1757-1759.
- Hall AJ and Barker DJ: Perthes' disease in Yorkshire. *J Bone Joint Surg Br* (1989) 71: 229-233.
- Barker DJ and Hall AJ: The epidemiology of Perthes' disease. *Clin Orthop Relat Res* (1986) 209: 89-94.
- Catterall A: Children's Orthopaedics and Fractures. Michael K.D. Benson, John A. Fixsen and Malcolm F. Macnicol eds, 1st Ed, New York, New York (1994): pp 443-457.
- Mercer Rang: The art and practice of children's orthopaedics. Dennis R. Mercer Rang eds, 1st Ed, Raven Press, Ltd. New York, New York (1992): pp 297-330.
- Amador A, Steger RW, Bartke A, Johns A, Hayashi RH and Stallings MH: Pituitary and testicular function in spontaneously hypertensive rats. *J Androl* (1983) 4: 67-70.
- Wright GL and Rankin GO: Concentration of ionic and total calcium in plasma of four models of hypertension. *Am J Physiol* (1982) 243: H365-370.
- McCarron DA, Yung NN, Ugoretz BA and Krutzik S: Disturbances of calcium metabolism in the spontaneously hypertensive rat. *Hypertension* (1981) 33: 162-167.
- Chapman EM: Thyroid function in Legg-Perthes disease. *N Engl J Med* (1956) 255: 289-290.
- Iwasaki K and Hirano T: Osteonecrosis and ossification disturbance of the femoral head in spontaneously hypertensive rats. *Nippon Seikeigeka Gakkai Zasshi* (1988) 62: 1003-1010 (in Japanese).
- Hirano T, Iwasaki K, Sagara K, Nishimura Y and Kumashiro T: Necrosis of the femoral head in growing rats. Occlusion of lateral epiphyseal vessels. *Acta Orthop Scand* (1989) 60: 407-410.
- Sagara K: Avascular necrosis in the femoral head of spontaneously hypertensive rats—correlation between microangiographic and histological findings. *Nippon Seikeigeka Gakkai Zasshi (J Jpn Orthop Assoc)* (1990) 64: 240-248 (in Japanese).
- Kikkawa M, Imai S and Hukuda S: Altered postnatal expression of insulin-like growth factor-I (IGF-I) and type X collagen preceding the Perthes' disease-like lesion of a rat model. *J Bone Miner Res* (2000) 15: 111-119.
- Kawahara T, Shimokawa I, Tomita M, Hirano T and Shindo H: Effects of Caloric Restriction on Development of the Proximal Growth Plate and Mtaphysis of the Caput Femoris in Spontaneously Hypertensive Rats: Microscopic and Computer-Assisted Image Analyses. *Microscopy research and technique* (2002) 59: 306-312.
- Shibahara M, Nishida K, Asahara H, Yoshikawa T, Mitani S, Kondo Y and Inoue H: Increased Osteocyte Apoptosis during the Development of Femoral Head Osteonecrosis in Spontaneously Hypertensive Rats. *Acta Med Okayama* (2000) 54: 67-74.
- Hunziker EB, Wagner J and Zapf J: Differential effects of insulin-like growth factor I and growth hormone on developmental stages of rat growth plate chondrocytes in vivo. *J Clin Invest* (1994) 93: 1078-1086.
- Neidel J, Zander D and Hackenbroch MH: Low plasma levels of insulin-like growth factor 1 in Perthes' disease. A controlled study of 59 consecutive children. *Acta Orthop Scand* (1992) 63: 393-398.
- Kim HK, Bian H, Randall T, Garces A, Gerstenfeld LC J and Einhorn TA: Increased VEGF expression in the epiphyseal cartilage after ischemic necrosis of the capital femoral epiphysis. *Bone Miner Res* (2004) 19: 2041-2048.
- Petersen W, Tsokos M and Pufe T: Expression of VEGF₁₂₁ and VEGF₁₆₅ in hypertrophic chondrocytes of human growth plate and epiphyseal cartilage. *J Anat* (2002) 201: 153-157.
- Engsig MT, Chen QJ, Vu TH, Pedersen AC, Therkidsen B, Lund LR, Henriksen K, Lenhard T, Foged NT, Werb Z and Delaisse JM: Matrix metalloproteinase 9 and vascular endothelial growth factor are essential for osteoclast recruitment into developing long bones. *J Cell Biol* (2000) 151: 879-889; Erratum, (2001)152: following 417.
- Slomiany MG and Rosenzweig SA: Autocrine effects of IGF-I-induced VEGF and IGFBP-3 secretion in retinal pigment epithelial cell line ARPE-19. *Am J Physiol Cell Physiol* (2004) 287: C746-753.
- Carlevaro MF, Cermelli S, Cancedda R and Descalzi Cancedda F: Vascular endothelial growth factor (VEGF) in cartilage neovascularization and chondrocyte differentiation: auto-paracrine role during endochondral bone formation. *J Cell Sci* (2000) 113: 59-69.
- Wickman A, Isgaard J, Adams MA and Friberg P: Differential regulation of IGF-1, its receptor and GH receptor mRNAs in the right ventricle and caval vein in volume-loaded genetically hypertensive rats. *J Endocrinol* (1999) 161: 263-271.
- Nolan BP, Senechal P, Waqar S, Myers J, Standley CA and Standley PR: Altered insulin-like growth factor-1 and nitric oxide sensitivities in hypertension contribute to vascular hyperplasia. *Am J Hypertens* (2003) 16: 393-400.
- Fisher RL: An epidemiological study of Legg-Perthes disease. *J Bone Joint Surg Am* (1972) 54: 769-778.
- Tanaka H, Tamura K, Takano K, Inoue N, Yoshioka H, Odera K, Takaya Y, Ono T, Ando H and Taguchi Y: Serum somatomedin A in Perthes' disease. *Acta Orthop Scand* (1984) 55: 135-140.
- Grasemann H, Nicolai RD, Hauffa BP, Reinhardt W, Nicolai H and Hovel M: Skeletal immaturity, IGF-1 and IGFBP-3 serum concentrations in Legg-Calve-Perthes disease (skeletal immaturity, IGF-1 and IGFBP-3 in LCPD). *Klin Padiatr* (1996) 208: 339-343.